



Revista Española de Cirugía Oral y Maxilofacial

Publicación Oficial de la SECOM CyC Sociedad Española de Cirugía Oral y Maxilofacial y de Cabeza y Cuello

Artículo Aceptado para su pre-publicación / Article Accepted for pre-publication

Título / Title:

Cirugía ortomórfica para la corrección de la dismorfología mandibular posterior a la anquilosis de la ATM - Un informe de 4 casos y revisión de la literatura. / Orthomorphic surgery for correction of mandibular dysmorphology post TMJ ankylosis - A report of 4 cases and review of literature

Autores / Authors:

VARUN SHUKLA, SAIKRISHNA DEGALA

DOI: [10.20986/recom.2023.1433/2023](https://doi.org/10.20986/recom.2023.1433/2023)

Instrucciones de citación para el artículo / Citation instructions for the article:

SHUKLA VARUN, DEGALA SAIKRISHNA . Cirugía ortomórfica para la corrección de la dismorfología mandibular posterior a la anquilosis de la ATM - Un informe de 4 casos y revisión de la literatura. / Orthomorphic surgery for correction of mandibular dysmorphology post TMJ ankylosis - A report of 4 cases and review of literature. j.maxilo 2023. doi: 10.20986/recom.2023.1433/2023.



Este es un archivo PDF de un manuscrito inédito que ha sido aceptado para su publicación en la *Revista Española de Cirugía Oral y Maxilofacial*. Como un servicio a nuestros clientes estamos proporcionando esta primera versión del manuscrito en estado de prepublicación. El manuscrito será sometido a la corrección de estilo final, composición y revisión de la prueba resultante antes de que se publique en su forma final. Tenga en cuenta que durante el proceso de producción se pueden dar errores, lo que podría afectar el contenido final. El copyright y todos los derechos legales que se aplican al artículo pertenecen a la *Revista Española de Cirugía Oral y Maxilofacial*.

ORTHOMORPHIC SURGERY FOR CORRECTION OF MANDIBULAR DYSMORPHOLOGY POST TMJ ANKYLOSIS. A REPORT OF 4 CASES AND REVIEW OF LITERATURE

CIRUGÍA ORTOMÓRFICA PARA LA CORRECCIÓN DE LA DISMORFOLOGÍA MANDIBULAR POSTERIOR A LA ANQUILOSIS DE LA ATM. UN INFORME DE 4 CASOS Y REVISIÓN DE LA LITERATURA

Varun Shukla and Saikrishna Degala

Department of Oral & Maxillofacial Surgery. JSS Dental College & Hospital. Mysuru, India

CORRESPONDENCE:

Varun Shukla

v.shukla095@gmail.com

Recibido: 28-02-2023

Aceptado: 26-04-2023

ABSTRACT

Mandibular dysmorphism is predominantly a result of uncoordinated growth deficiency or surfeit. Unilateral temporomandibular joint ankylosis during the active growth phase, if left unoperated, brings about changes in the size and shape of the mandible and the surrounding structures. The use of orthognathic surgery in correcting the facial deformities arising from discrepancies in spatial relationships although well accepted is unable to correct anomalies arising from an altered morphology. The surgical correction using orthomorphic principles restore the morphology without changing the occlusal status, thus proving to be an invaluable addition to a maxillofacial surgeon's repertoire.

Four patients previously operated on for unilateral temporomandibular ankylosis having mandibular asymmetry were managed by orthomorphic correction. The etiological factor in all the recruited patients was trauma to the temporomandibular joint during childhood. The patients were evaluated for neurosensory changes, assessment of mouth opening before and after surgery, postoperative assessment of mandibular symmetry, and postoperative

complications on 3rd day, 3 weeks, and 3 months postoperatively. Good to moderate asymmetry correction was seen in all the cases. Mental nerve paraesthesia was noted in one patient. No postoperative complications were noted.

The described technique can be used as a complement to conventional orthognathic surgery or as a reliable single-stage treatment alternative for complex dysmorphic entities.

Keywords: Mandibular asymmetry, dysmorphology, temporomandibular joint ankylosis, orthomorphing surgery, case report.

RESUMEN

La dismorfología mandibular es predominantemente el resultado de una deficiencia o exceso de crecimiento no coordinado. La anquilosis unilateral de la articulación temporomandibular durante la fase de crecimiento activo, si no se opera, produce cambios en el tamaño y la forma de la mandíbula y las estructuras circundantes. El uso de la cirugía ortognática para corregir las deformidades faciales que surgen de las discrepancias en las relaciones espaciales, aunque bien aceptado, no puede corregir las anomalías que surgen de una morfología alterada. La corrección quirúrgica utilizando principios ortomórficos restaura la morfología sin cambiar el estado oclusal, lo que demuestra ser una adición invaluable al repertorio de un cirujano maxilofacial.

Cuatro pacientes previamente operados por anquilosis unilateral de la articulación temporomandibular que presentaban asimetría mandibular fueron tratados mediante corrección ortomórfica. El factor etiológico en todos los pacientes reclutados fue un traumatismo en la articulación temporomandibular durante la infancia. Los pacientes fueron evaluados para cambios neurosensoriales, evaluación de la apertura bucal antes y después de la cirugía, evaluación postoperatoria de la simetría mandibular y complicaciones postoperatorias al 3.^{er} día, 3 semanas y 3 meses después de la cirugía. Se observó una buena a moderada corrección de la asimetría en todos los casos. Se observó parestesia del nervio mentoniano en un paciente. No se observaron complicaciones postoperatorias. La técnica descrita se puede utilizar como complemento de la cirugía ortognática convencional o como una alternativa de tratamiento de una sola etapa confiable para entidades dismórficas complejas.

Palabras clave: Asimetría mandibular, dismorfología, anquilosis de la articulación temporomandibular, cirugía ortomórfica, informe de caso.

INTRODUCTION

Facial asymmetry can have lasting psychological effects, often resulting from mandibular dysmorphology. The dysmorphology may be caused by various factors, including uncoordinated growth, trauma, developmental abnormalities, and tumors¹. Unilateral temporomandibular joint (TMJ) ankylosis is a significant cause of mandibular dysmorphology in growing individuals, which, if left untreated, may cause significant changes to the mandible's morphological characteristics and underlying soft tissue structures. Surgical procedures like genioplasty, distraction osteogenesis, orthomorphics, and orthognathic surgery have been shown to correct mandibular dysmorphology. Orthomorphic surgery corrects morphology, while traditional orthognathic surgery corrects jaw function. In this report, four patients with mandibular dysmorphology secondary to unilateral TMJ ankylosis were surgically treated with orthomorphic correction to restore facial symmetry. The patients were evaluated for various outcomes, including mental nerve paraesthesia, pre- and post-surgical mouth opening, post-operative mandibular symmetry, and complications. These cases have been described in accordance with the CARE reporting checklist.

CASE DESCRIPTION

Case 1: A 30-year-old male presented to the Department of Maxillofacial Surgery with a flattened right side of the face since childhood. The patient underwent interpositional gap arthroplasty with bilateral coronoidectomy for right TMJ ankylosis 1 year back. On extraoral examination, clinically evident asymmetry was noted in the inferior mandibular border (Figure 1). The patient had a convex profile with incompetent lips and was diagnosed with mandibular asymmetry. Posteroanterior cephalogram and Grummon's analysis confirmed the diagnosis.

Case 2: A 20-year-old female reported to the department with a complaint of facial disfigurement over the left side of her face since birth. The patient provided us with a history of childhood trauma that led to left temporomandibular joint ankylosis and underwent interposition gap arthroplasty using temporalis muscle for the same, a month back. On extraoral examination, the patient had a convex profile with evident asymmetry with respect to the inferior border of the mandible (Figure 2). The diagnosis of mandibular asymmetry was arrived upon, which was confirmed with pre-operative CT scans. The DICOM images were transferred to 3D Dolphin software for virtual patient modelling (Figure 3).

Case 3: A 28-year-old female with the complaint of a flattened left side of the face since childhood reported to our department. The patient had a successful release of TMJ ankylosis on the left side 4 years back with interposition gap arthroplasty. On examination, the patient had an appreciable asymmetry of the mandible with a convex profile and incompetent lips (Figure 4). A preoperative Grummon's analysis was performed to confirm the diagnosis of mandibular asymmetry (Figure 5).

Case 4: A 16-year-old female presented to us with a complaint of left-sided facial disfigurement. She gave a history of undergoing resection of right TMJ ankylotic mass followed by interposition arthroplasty using temporalis muscle two years back. On examination patient presented with a convex facial profile, asymmetry of the mandible, and incompetent lips (Figure 6).

Written consent was obtained from the patients for undergoing the aforementioned procedure and for the publication of the case report and the accompanying images.

Surgical Procedure (Figure 7).

All surgeries were performed under general anaesthesia, with local anaesthetic infiltration (1:80,000 adrenaline) at the proposed incision site. Two lower vestibular incisions were used to access the ramal and mental regions, and a mucoperiosteal flap was raised to the inferior border of the mandible while carefully protecting the mental nerve. The surgery involved an eccentric genioplasty continuing along the corpus to a ramus lateral cortical osteotomy on the non-ankylotic aspect of the mandible. Full-thickness sectioning of the inferior border was performed adjacent to the area of eccentric fusion using a combination of rotary instruments and reciprocating saws. The use of piezoelectric scalpel is a potential improvement to this technique. The piezoelectric devices have demonstrated favourable outcomes in a recent systematic review and meta-analysis and have been found to reduce operative blood loss and

minimize neurosensory disturbances, while also being less traumatic in comparison to traditional saws². The anterior portion was mobilized and oriented to rectify the midline and reinstate the proposed vertical and anteroposterior relationship based on the preoperative analysis. Titanium mini plates were used for fixation, and an autogenous corticocancellous iliac bone graft was sandwiched along the overlying margins. Postoperative intravenous antibiotics and analgesics were administered, and the patients were assessed for mental nerve paraesthesia, mouth opening, and postoperative mandibular asymmetry at 3rd day, 3 weeks and 3 months postoperatively. The surgical team assessed post-operative facial symmetry using a 3 point scale (good, moderate, poor). Neurosensory changes were evaluated using Light touch sensation test and Brush directional strokes test. Interincisal clearance was measured using a Willis's gauge. During the follow-up period of 1 year, there were no reported cases of relapse. The patients expressed contentment with the results of the surgical intervention.

Employing Dolphin Imaging software 11.8 (Dolphin Imaging and Management Solutions, Chatsworth, USA), a 3-D virtual model of patient 2 was constructed, followed by marking the virtual mandibular osteotomies in two segments. The virtual treatment involved lateral mobilization of the osteotomized segments to correct frontal asymmetry (Figure 3).

The lack of financial resources among the remaining patients prevented the utilization of 3-D virtual planning. Consequently, cephalometric analysis was used for assessment purposes.

Discussion

Salins and colleagues¹ described the orthomorphic correction as “an eccentric genioplasty from the body reaching to the buccal cortex of the mandible”. The section transitions from the full thickness of the body to a sagittally oriented buccal cortical osteotomy in the ramal region. After that, the fragment is positioned to address the anteroposterior and midline deficit. Patients with a normal ramus dimension, functional occlusion, insufficient/ standard posterior airway space, or unilateral ankylosis may benefit from orthomorphic osteotomies³. The study authors noted that mental nerve paraesthesia is a common complication associated with orthomorphic correction for mandibular dysmorphology. In a previous study, the authors reported that two out of five patients (40 %) undergoing orthomorphic correction experienced mental nerve paresthesia. Similarly, Lindquist et al reported alteration in lower lip and chin sensation in 28.5 % of patients following sagittal split osteotomy when performed concurrently with genioplasty. Furthermore, isolated genioplasty resulted in neurosensory

changes in 10 % of patients⁴. In contrast, the current study found that only one patient experienced mental nerve paresthesia. The study authors suggested that the damage to the mental nerve in this case may be due to the shortened height of the body of the ramus, and that leaving a fringe of soft tissue in the premolar region during incision-making could help avoid such damage.

Postoperative mouth opening reduction was due to discomfort and edema, resolving at 3 months. The assessment of postoperative symmetry was deemed satisfactory in three cases, indicating good symmetry, while in one case the assessment showed a moderate level of symmetry (Figure 8). The results were similar to the authors' previous results with this technique i.e., 60 % of cases showed good mandibular symmetry while 40 % showed moderate symmetry⁵. No postoperative complications were observed, but the follow-up period was deemed insufficient to assess graft resorption (Table I). The technique's limitations include imperfect symmetry and deficient mandibular body in some patients. The preoperative and postoperative remained unaltered as orthomorphologic correction focuses on correcting the shape and contour-related deformities without impacting the occlusal status¹. Since its inception, very little literature exists regarding its use in the correction of mandibular dysmorphology, mostly in the form of isolated case reports.

Pipalia et al.⁶ used 3D virtual patient modelling for orthomorphologic surgical simulation in a 23-year-old female with facial asymmetry, diagnosed as left condylar hypoplasia. Rudagi et al.⁷ demonstrated the successful correction of facial asymmetry in a 27-year-old Marfan syndrome patient presenting unilateral TMJ joint ankylosis, obstructive sleep apnoea, and unesthetic contour to correct the residual facial deformity.

With the advent of virtual surgical planning, most surgeons have forgone the extensive laboratory preparations synonymous with the conventional surgical work-up⁸. Three-dimensional imaging has expanded our stability to assess and plan orthomorphologic surgery by eliminating the ambiguity associated with 2D imaging⁹.

Orthomorphologic surgery effectively corrects bony tissues, producing significant transformations and correcting soft tissue deficiencies in various conditions.

In the reported cases, the patients exhibited unwillingness to undergo orthodontic correction and expressed a strong desire for aesthetic improvement. Therefore, a single stage surgery for correction of mandibular asymmetry was undertaken instead of conventional orthognathic surgery.

Compared to the conventional orthognathic surgery and more recent chin augmentation procedures using PEEK or polyethylene (Medpor) implants, orthomorphic surgery has certain limitations. Firstly, orthomorphic correction confers less predictable and proportional changes to the facial contour than orthognathic surgery. Secondly, it is incapable to correct the occlusal cant, a common finding in patients with unilateral temporomandibular joint ankylosis. Thirdly, the need for autologous bone grafts increases the operative time and adds morbidity compared to alloplastic chin augmentation procedures. PEEK, a durable and malleable biomaterial, is conducive to intraoperative modifications. In addition, the ability to prefabricate an implant based on the patient's anatomy can decrease operating time and result in more precise custom fit, in contrast to orthomorphic surgery¹⁰.

CONCLUSION

Orthomorphic surgery is more than just a necessary complement to orthognathic surgery. It gives the surgeon a reliable single-stage treatment alternative for complex mandibular dysmorphic structures. The described technique can modify the entire region of the contour defect as a single unit, in any desired dimension.

ETHICAL STATEMENT

The institutional ethical committee of JSS Dental College has stated that an ethical approval is not pertinent for the description of the above-mentioned clinical cases.

REPORTING CHECKLIST

The authors have completed the CARE reporting checklist.

CONFLICT OF INTEREST

All authors have completed the ICMJE uniform disclosure form. The authors have no conflicts of interest to declare.

REFERENCES

1. Salins PC, Venkatraman B, Kavarody M. Morphometric basis for orthomorphic correction of mandibular asymmetry. *J Oral Maxillofac Surg.* 2008;66(11):1523-31. DOI: 10.1016/j.joms.2007.06.683.
2. Pagotto LEC, de Santana Santos T, de Vasconcellos SJA, Santos JS, Martins-Filho PRS. Piezoelectric versus conventional techniques for orthognathic surgery: Systematic review and meta-analysis. *J Craniomaxillofac Surg.* 2017;45(10):1607-13. DOI: 10.1016/j.jcms.2017.06.011.
3. Anchlia S. Temporomandibular Joint Ankylosis. In: Bonanthaya K, Panneerselvam E, Manuel S, Kumar VV, Rai A, eds. *Oral and Maxillofac Surgery for the Clinician.* Singapore: Springer; 2021.
4. Lindquist CC, Obeid G. Complications of genioplasty done alone or in combination with sagittal split-ramus osteotomy. *Oral Surg Oral Med Oral Pathol.* 1988;66(3):13-6.
5. Degala S, Shetty S, Morgan G. A study on orthomorphic correction of mandibular dysmorphology. *Ann Maxillofac Surg.* 2011;1(2):120. DOI: 10.4103/2231-0746.92774.
6. Pipalia H, Ganesh P, Shetty S, Salins PC, Raut R, Boyina KK. Virtual surgery planning in orthomorphic correction of mandibular dysmorphology. *J Craniomaxillofac Surg.* 2016;27(8):2156-8. DOI: 10.1097/SCS.00000000000003117.
7. Rudagi BM, Rishabh J, Arif M, Namrata C, Shahbaaz N, Gaurav B. Management of unilateral temporomandibular joint ankylosis & orthomorphic correction in a patient with Marfan syndrome: A rare case report. *Int J Surg Case Rep.* 2020;75:157-61. DOI: 10.1016/j.ijscr.2020.09.033.
8. Gateno J, Xia JJ, Teichgraeber JF, Christensen AM, Lemoine JJ, Liebschner MA, et al. Clinical feasibility of computer-aided surgical simulation (CASS) in the treatment of complex cranio-maxillofacial deformities. *J Oral Maxillofac Surg.* 2007;65(4):728-34. DOI: 10.1016/j.joms.2006.04.001.
9. Chen K, Xiao D, Abotaleb B, Chen H, Li Y, Zhu S. Accuracy of Virtual Surgical Planning in Treatment of Temporomandibular Joint Ankylosis Using Distraction Osteogenesis: Comparison of Planned and Actual Results. *J Oral Maxillofac Surg.* 2018;76(11):2422.e1-2422.e20. DOI: 10.1016/j.joms.2018.07.003.

10. Järvinen S, Suojanen J, Kormi E, Wilkman T, Kiukkonen A, Leikola J, Stoor P. The use of patient specific polyetheretherketone implants for reconstruction of maxillofacial deformities. *J Craniomaxillofac Surg.* 2019;47(7):1072-6. DOI: 10.1016/j.jcms.2019.03.018.

Prepublicación

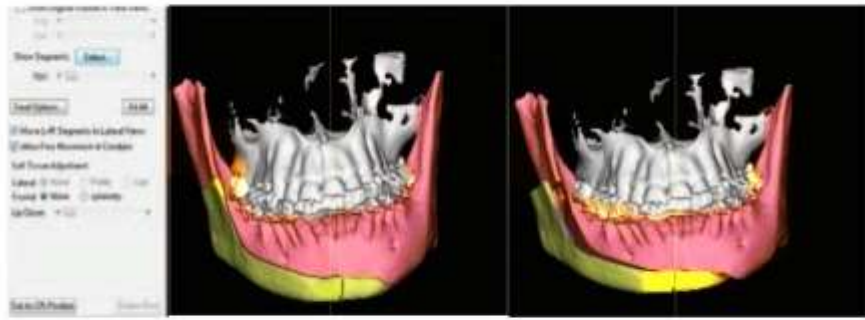
Figure 1. Preoperative and postoperative images (Case 1).

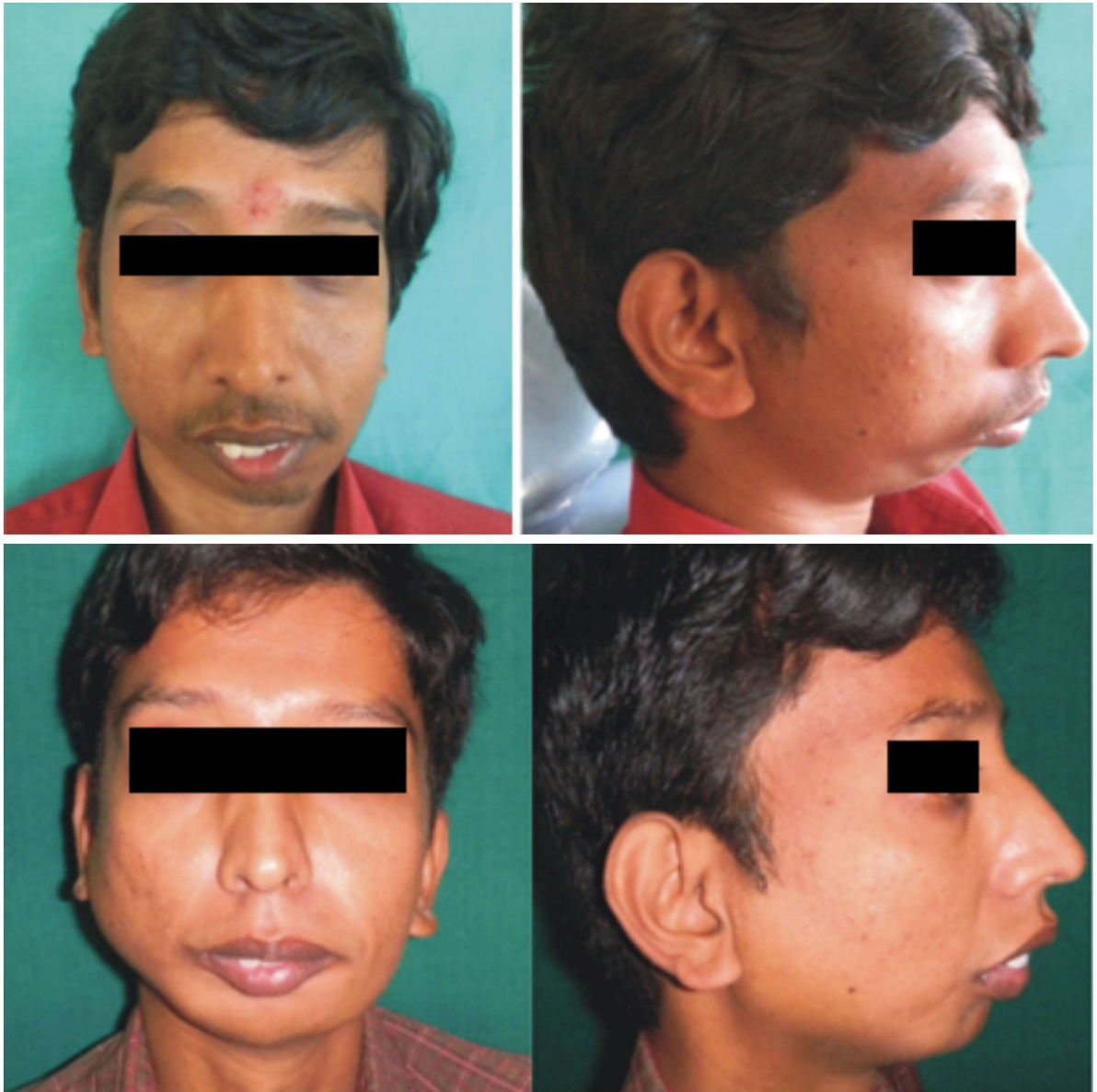

Figure 2. Preoperative and postoperative images (Case 2).

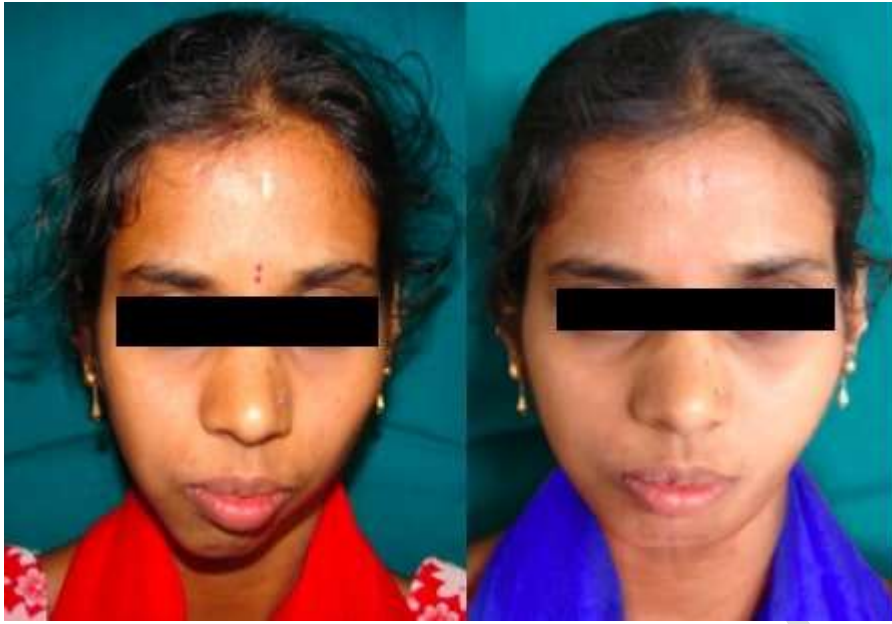

Figure 3. Virtual osteotomy and repositioning of the osteotomized segment.



Prepublica

Figure 4. Preoperative and postoperative images (Case 3).

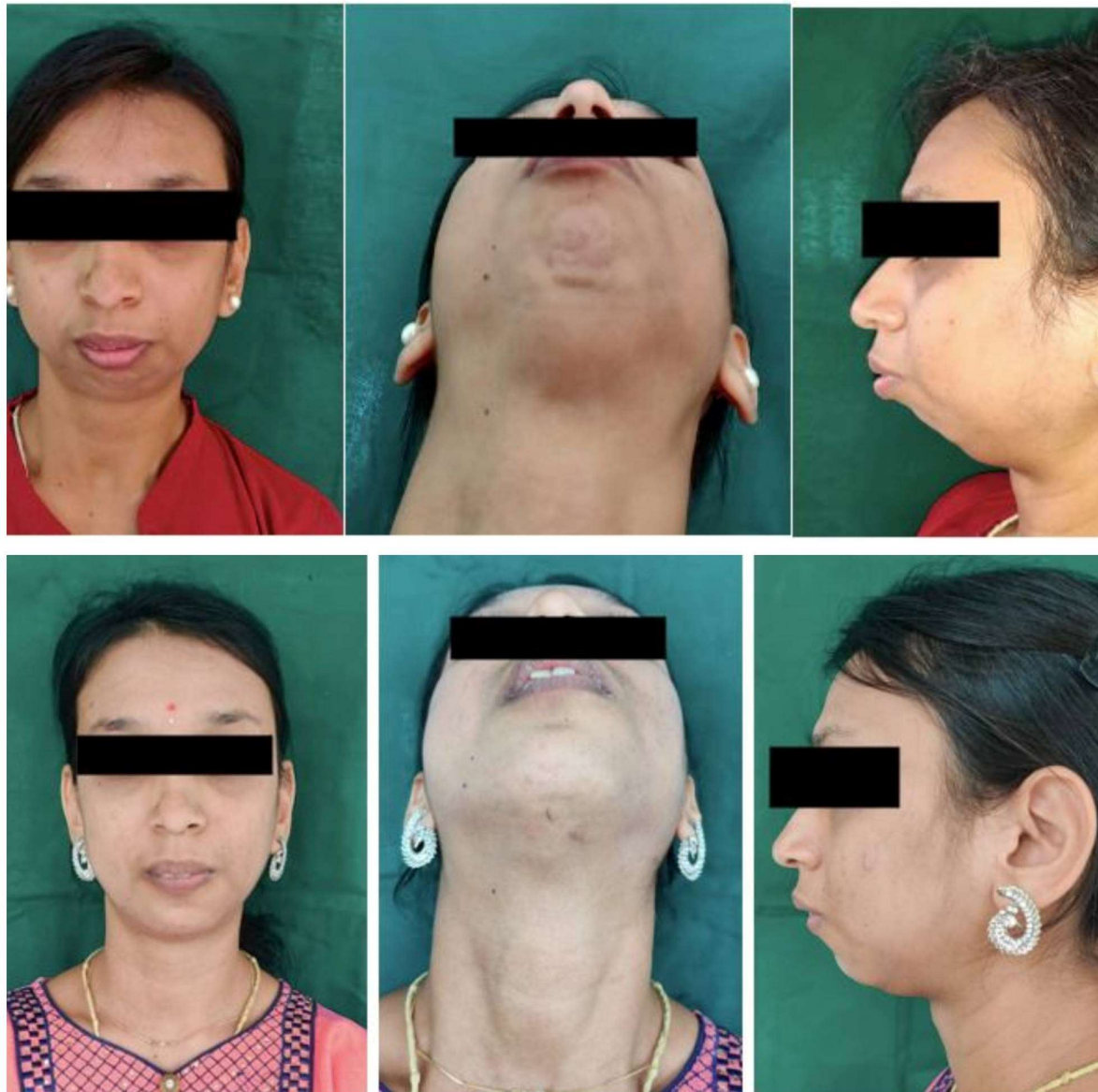

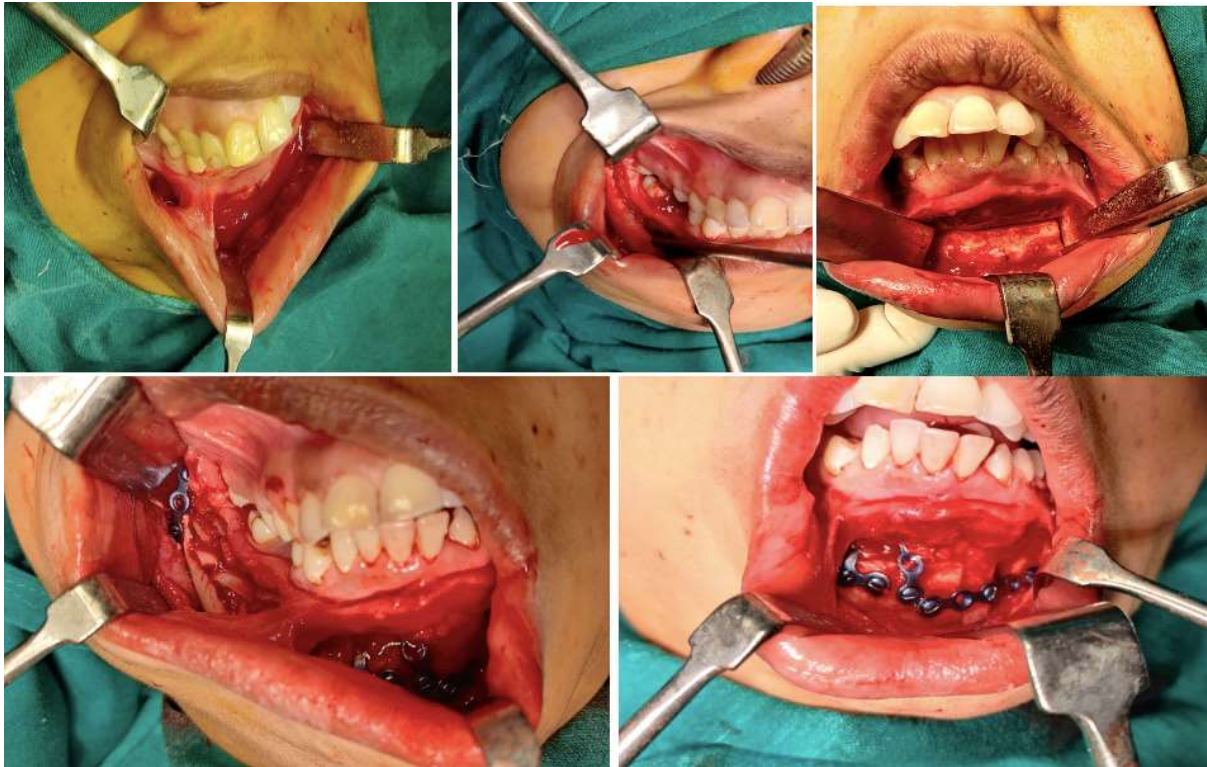
Figure 5. Preoperative Grummon's analysis (Case 3) showing a deficiency of 8mm on the right side.

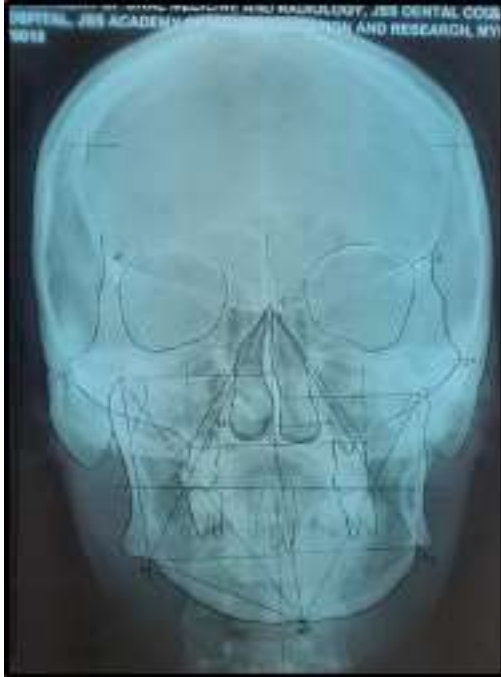

Figure 6. Preoperative and postoperative images (Case 4).

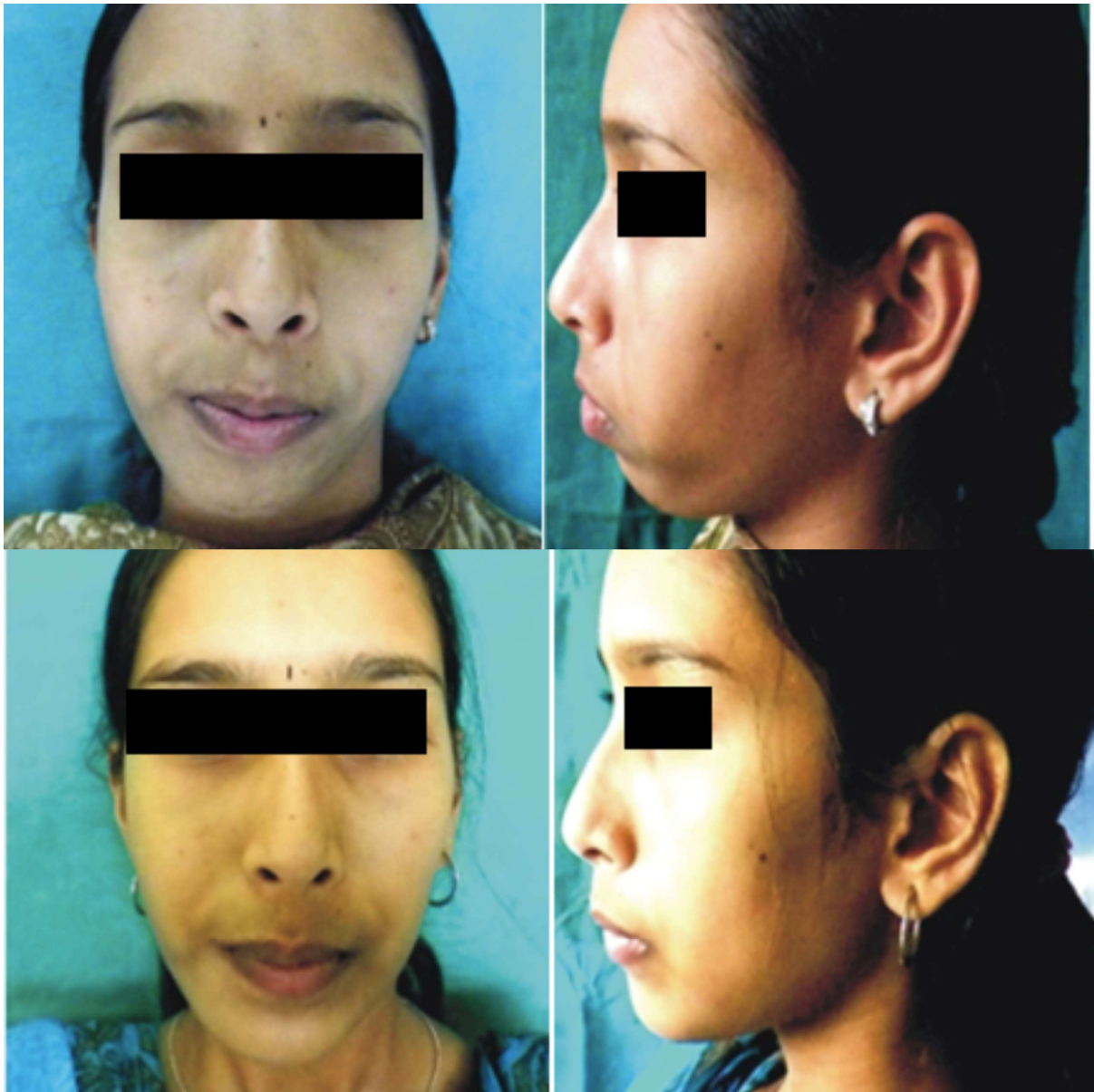

Figure 7. Intraoperative photographs (A) Incision design (B) Corpus osteotomy (C) Mobilization of the anterior segment (D) The overlapping edges sandwiched with autogenous corticocancellous anterior iliac crest graft (E) Final position and rigid fixation with Titanium miniplates.



Prepublik

Figure 8. The image displays a PA Cephalogram depicting the radiographic changes that occurred before and after orthomorphologic surgery.

