



Artículo Aceptado para su pre-publicación / Article Accepted for pre-publication

Título / Title:

Reposicionamiento meniscal de la articulación temporomandibular con minitornillos de anclaje MITEK: estudio clínico y por RM a medio plazo / Temporomandibular joint disc repositioning with MITEK miniscrew anchor: a medium-term follow up clinical and MRI study.

Autores / Authors:

Marta Maria Pampin Martínez, Jose Luis del Castillo Pardo de Vera, Jorge Guiñales Diaz de Cevallos, Víctor Dueso Delgado, Jose Luis Cebrian Carretero

DOI: [10.20986/recom.2021.1298/2021](https://doi.org/10.20986/recom.2021.1298/2021)

Instrucciones de citación para el artículo / Citation instructions for the article:

Pampin Martínez Marta Maria, del Castillo Pardo de Vera Jose Luis, Guiñales Diaz de Cevallos Jorge , Dueso Delgado Víctor , Cebrian Carretero Jose Luis .

Reposicionamiento meniscal de la articulación temporomandibular con minitornillos de anclaje MITEK: estudio clínico y por RM a medio plazo / Temporomandibular joint disc repositioning with MITEK miniscrew anchor: a medium-term follow up clinical and MRI study. . j.maxilo 2021. doi: 10.20986/recom.2021.1298/2021.



Este es un archivo PDF de un manuscrito inédito que ha sido aceptado para su publicación en la *Revista Española de Cirugía Oral y Maxilofacial*. Como un servicio a nuestros clientes estamos proporcionando esta primera versión del manuscrito en estado de prepublicación. El manuscrito será sometido a la corrección de estilo final, composición y revisión de la prueba resultante antes de que se publique en su forma final. Tenga en cuenta que durante el proceso de producción se pueden dar errores, lo que podría afectar el contenido final. El copyright y todos los derechos legales que se aplican al artículo pertenecen a la *Revista Española de Cirugía Oral y Maxilofacial*.

TEMPOROMANDIBULAR JOINT DISC REPOSITIONING WITH MITEK MINISCREW ANCHOR: A MEDIUM-TERM FOLLOW-UP CLINICAL AND MR STUDY

REPOSICIONAMIENTO MENISCAL DE LA ARTICULACIÓN TEMPOROMANDIBULAR CON MINITORNILLOS DE ANCLAJE MITEK: ESTUDIO CLÍNICO Y POR RM A MEDIO PLAZO

Marta María Pampín Martínez¹, José Luis del Castillo Pardo de Vera¹, Jorge Guiñales Díaz de Cevallos¹, Víctor Dueso Delgado¹, José Luis Cebrián Carretero^{1,2}

¹Servicio de Cirugía Oral y Maxilofacial. Hospital Universitario La Paz. Madrid, España.

²Servicio de Cirugía Oral y Maxilofacial. Hospital La Luz. Madrid, España

CORRESPONDENCIA:

Marta María Pampín Martínez

mpampin@ucm.es

Recibido: 29-06-2021

Aceptado: 26-10-2021

RESUMEN

Introduction: Anterior disc displacement is the most frequent internal derangement of the TMJ. It can ultimately lead to progressive joint dysfunction. Several disc repositioning techniques have been described, both open and arthroscopic. There is a lack of consensus regarding the success of open disc repositioning. Nonetheless, many authors have reported satisfactory results.

Material and methods: We report our experience with disc repositioning using the MITEK mini anchor in 25 patients. Preoperative pain measured by the VAS scale, clicking and TMJ related symptoms were recorded, as well as mean mouth opening. Patients underwent a postoperative MRI to analyze disc position at 1 year after surgery.

Results: Five patients (20 %) presented with persistent pain after surgery and ten patients (40 %) referred persistent clicking at the longest follow-up. Preoperative mean maximum mouth opening was 29,28 mm, which increased to 36,08 mm one-year

postoperatively. Mean pain as measured by the VAS scale decreased to 2,40 after surgery, with a total decrease of 4,16 points. On MRI, 23 of 30 discs were correctly positioned (76,66 %) at 1 year after surgery.

Conclusion: Disc repositioning has shown to significantly decrease pain and TMJ-related symptoms. However, we found that there is a remarkable clinical and radiological discrepancy that must be taken into account.

Palabras clave: Disc repositioning, meniscopexy, MITEK anchor.

RESUMEN

Introducción: El desplazamiento anterior del disco es el trastorno interno más frecuente de la ATM. Si evoluciona, puede provocar una disfunción articular progresiva. Se han descrito varias técnicas de reposicionamiento del disco, tanto abiertas como artroscópicas. Sin embargo, existe una falta de consenso respecto a la eficacia de la cirugía abierta para reposicionamiento meniscal, a pesar de que en la literatura muchos autores han demostrado resultados satisfactorios.

Material y métodos: Presentamos nuestra experiencia con el reposicionamiento meniscal utilizando MITEK en 25 pacientes. Se registró el dolor preoperatorio medido por la escala EVA, los clics y los síntomas relacionados con la ATM, así como la apertura oral media. Los pacientes fueron sometidos a una resonancia magnética postoperatoria para analizar la posición del disco un año después de la cirugía.

Resultados: Cinco pacientes (20 %) presentaron dolor persistente después de la cirugía y diez pacientes (40 %) refirieron clics persistentes al final del seguimiento. La apertura oral media máxima preoperatoria fue de 29,28 mm, que aumentó a 36,08 mm un año después de la cirugía. El dolor medio medido por la escala EVA disminuyó a 2,40 después de la cirugía, con una disminución total de 4,16 puntos. En la resonancia magnética, 23 de los 30 discos (76,66 %) estaban adecuadamente posicionados 1 año después de la cirugía.

Conclusión: Se ha demostrado que el reposicionamiento del disco reduce significativamente el dolor y los síntomas relacionados con la ATM. Sin embargo,

encontramos que existe una notable discrepancia clínica y radiológica que debe tenerse en cuenta.

Palabras clave: Reposicionamiento meniscal, meniscopexia, MITEK.

INTRODUCTION

Anterior disc displacement is one of the most common temporomandibular joint (TMJ) disorders which can initiate a cascade of events leading to arthritis and other TMJ-related symptoms¹.

Disc displacement can incite inflammatory changes that can cause osteoarthritis and progressive degenerative joint disease, which is characterized by the deterioration of the articular cartilage, disc, synovium, and subchondral bone².

Although some patients may lack visible symptoms, the condition can affect normal jaw functioning such as chewing, swallowing, and phonetics³.

Some authors have stated that, without proper treatment, this condition can lead to the degeneration of the disc and consequent condylar remodeling and resorption, which ultimately decreases condylar height and can result in facial asymmetry².

There is an intense ongoing debate on the treatment of disc displacement. Annandale⁴ first described surgical disc repositioning in 1887. Afterwards, in 1979, McCarty and Farrar⁵ reported a 94 % success rate in disc repositioning surgery.

Since then, different surgical modifications and refinements have been proposed in the literature. In 2001, Wolford⁶ modified disc repositioning surgery with an anchoring device to maintain the new position of the articular disc.

In the last decades, with the rise of endoscopic and minimally invasive surgery, arthroscopic disc repositioning techniques have also been described.

However, evidence about the success of TMJ disc repositioning techniques is still controversial. Unanimous and solid clinical guidance is still needed to surgically treat TMJ internal derangement, especially when associated to dentofacial deformities.

In this article, we report our experience with the MITEK mini anchor for surgical disc repositioning of the TMJ and describe the mid-term follow-up and our MRI findings.

MATERIAL AND METHODS

The MITEK mini anchor is made of a body and two retention devices, composed of 90 % titanium metal alloy, 6 % aluminum and 4 % vanadium. Its axis has a diameter of 1.8 mm and a length of 5.0 mm with an eyelet to place the suture (2.0 Ethibond® braided polyester suture). The retention devices are made of titanium and nickel, providing this anchor with great elasticity. In previous studies, this anchor has shown to provide adequate bone integration and long-term stability. However, postoperative MRI evaluation can be hampered due to the artifact effect of the anchor.

We performed a retrospective study where we selected patients who underwent surgical repositioning of the TMJ disc between august 2015 and January 2020.

Patients with Wilkes stage II or III who presented with persistent pain or limited mouth opening despite > 6 months of conservative treatment were selected for arthroplasty and disc repositioning using the MITEK mini anchor. All patients received preoperative MRI examination (with sequences in closed and open mouth) and postoperative MRI, which was performed at 1 year after surgery and was evaluated by both a TMJ specialist and a radiologist with experience in evaluating TMJ diseases.

Inclusion criteria included patients who underwent surgical repositioning of the TMJ disc using the MITEK mini anchor, patients with Wilkes stage II and III in the MRI, patients with salvageable articular disc and absence of perforations, patients who underwent both unilateral and bilateral procedures and patients with preoperative and postoperative available MRI.

Exclusion criteria included patients who underwent disc repositioning via arthroscopic procedures; patients who underwent surgical repositioning using other screw different from MITEK mini anchor; patients who had had previous TMJ surgery, patients who underwent simultaneous orthognathic surgery, patients without preoperative or postoperative MRI or those whose MRI could not be properly interpreted due to the presence of artifacts.

Symptoms (pain measured by the VAS scale, clicking, mouth opening limitation) and maximum interincisal opening (in mm) were evaluated preoperatively and postoperatively. Examination in the follow-up at 1 week postoperatively, 1 month, 6 months, 1 year after surgery and longest follow-up was recorded. Mean increase in

mouth opening (MIO) was calculated for all patients at one-year postoperatively. Continuous variables (MIO) were analyzed with the Student t-test for paired samples and by analysis of variance. We used the SPSS 26.0 version for this analysis. MRI evaluation was performed at one year after surgery by a specialized radiologist to evaluate the position of the disc (Figure 1).

Surgery was performed via a standard endaural approach under general anesthesia. The anterior release of the disc was performed by placing an incision with electrocautery approximately 2 mm anterior to the disc in a medial to lateral fashion. Any disc adhesences or fibrous tissue were also incised and eliminated. The retrodiscal tissue was coagulated. Proper disc release was checked, and the disc was repositioned over the condyle head. Then, two MITEK mini screw was positioned in the posterior condyle, approximately 8-10 mm inferior to the condylar sloop. The two horizontal mattress sutures were placed in the most posterior part of the disc, at the junction with the retrodiscal tissue. Several knots (6-7 knots) were done to secure the suture and enough tension was applied to overcorrect the disc, such that the posterior band was placed in a 2 o'clock position over the condylar head (Figure 2). Finally, the position of the disc was checked by opening and closing the mouth and closure of the joint capsule and endaural approach was performed.

Patients were discharged the day after surgery. A soft diet was recommended for at least 3-4 weeks after surgery. Also, physiotherapy was recommended after 1 week postoperatively and during the first months to improve mandibular, which included a series of gradual active exercises which consisted of mouth opening and lateral and protrusive movements.

RESULTS

A total of 25 patients were included, 2 men (8 %) and 23 women (92 %). Five of the 25 patients underwent bilateral disc repositioning (20 %), accounting for a total of 30 discs that were repositioned.

Mean age was 36,4 years (range 19-49 years). Mean postoperative follow-up time was 20 months (range 12-37 months). The most frequent symptom reported by these

patients was pain (92 %), with a mean VAS scale value of 6,56 (Range [6-8]), clicking (48 %) and blocking (28 %).

Preoperative mean maximum mouth opening was 29,28 mm, which increased to 36,08 mm one-year postoperatively, meaning a final increase of 6,8 mm, which was statistically significant ($p < 0,05$) (Figure 3).

5 patients (20 %) presented with persistent pain after surgery, and ten patients (40 %) referred persistent clicking at the longest follow-up. A comparative chart between preoperative and postoperative symptoms is displayed in Figure 4. Three patients (12 %) referred muscular pain in the masseter which resolved with myorelaxant treatment. Mean pain as measured by the VAS scale decreased to 2,40 after surgery (Range [0-5]), with a total decrease of 4,16 points (Figure 5).

In the MRI evaluation, we found that 23 of 30 discs were correctly positioned (76,66 %). On the contrary, 7 of 30 discs were displaced in the postoperative MRI and had relapsed (23,33 %).

DISCUSSION

Both surgical and nonsurgical methods have been proposed to treat temporomandibular disorders over the years. The surgical approaches are now varied and diverse ranging from minimally invasive procedures, such as arthrocentesis or arthroscopy, to more extensive surgical options, such as discectomy, condylectomy and disc repositioning techniques with or without anchors⁷.

The most common temporomandibular disorder is the internal derangement of the temporomandibular joint, which is often accompanied by disc displacement and produces clinical dysfunction and joint pain⁸.

This condition is related to an abnormal relationship between the disc and the mandibular condyle, being a common cause of temporomandibular joint (TMJ) pain and functional alteration⁹.

Many papers have reported that anterior disc displacement is a common incidental finding on MRI, even in asymptomatic individuals. However, it has been stated that disc displacement may have a role in the pathogenesis of degenerative changes happening in the TMJ¹⁰. This is explained by the loss of protection provided by the disc when it is

displaced, which can lead to inflammation and joint effusion. When the disc is anteriorly displaced, the vessel rich posterior band begins to deteriorate as the tissue experiences cyclic ischemia and reperfusion injury caused by excessive loading and, ultimately, this leads to constant inflammation and degeneration of the cartilaginous structures that comprise the joint².

Disc repositioning is a procedure to eliminate mechanical interference, to relieve pain and to improve the range of motion¹¹. The goal of disc repositioning procedures is to reposition and stabilize the disc, to re-establish the normal condyle-disc relation to prevent any joint degenerative changes and keep normal joint function. He and colleagues¹¹ observed condylar bone regeneration after the disc was surgically repositioned in growing patients. Furthermore, Hu¹² found that displaced discs without reduction could become severely deformed and lead to shortening of the height of condyle. Therefore, unilateral disc displacement can be associated to mandibular asymmetry, while bilateral disc displacement can be associated to mandibular retrusion^{11,12}.

There is high controversy among maxillofacial surgeons about the results of disc repositioning and is still a procedure based on limited and controversial evidence. However, it is also greatly influenced by the surgeon's experience and preferences and the current literature available on the effectiveness of open joint TMJ disc repositioning meets the "patient-oriented evidence that matters"¹.

There are mainly two techniques of disc repositioning. The first is the arthroscopic technique, which has proven to be an effective option in cases of early internal derangements but is often inadequate for patients with a longstanding history of disc displacement². There are some arthroscopic techniques of disc fixation, such as suture discopexy (dynamic techniques) or fixation by screws or pins (static techniques)⁸. Nonetheless, this procedure is technically demanding for most surgeons. The second is the open reduction and fixation. In patients with long-standing disc displacement, this latter one would be the preferred option.

Wolford and coworkers⁶ have analyzed the outcomes of disc repositioning of the TMJ articular disc in different articles, focusing mainly on orthognathic surgery patients. Wolford used in 2001 the Mitek anchor to secure the repositioned articular disc. They studied patients with previous TMJ internal derangement who underwent orthognathic

surgery and TMJ disc repositioning with MITEK anchors concomitantly. In 1993 Wolford and Cardenas¹³ addressed idiopathic condylar resorption and showed 12 successfully treated patients who underwent open TMJ disc repositioning with a titanium mini anchor and concomitant double jaw surgery for mandibular advancement. They did not observe significant relapses and, furthermore, 5 patients showed a slight increase in condylar height (mean 0.4 mm). Later, Mehra and Wolford³ also evaluated 88 patients who simultaneously underwent orthognathic surgery and disc repositioning. They found an improvement in TMJ noises, pain and jaw function, referring stable occlusal and skeletal results.

Gonçalves¹ proposed several situations where the disc repositioning with the Mitek anchor demonstrated a high success rate: disc repositioning within 4 years of the onset of the displacement; adolescent internal condylar resorption patients who are treated within the first 4 years of the disease; no history of connective tissue autoimmune diseases; good remaining anatomy of the disc; reducing discs; no other joint involvement; no recurrent gastrointestinal, urinary, or respiratory tract problems and no history of sexually transmitted diseases. He also analyzed 3-dimensional condylar changes after maxillomandibular surgical advancement with and without TMJ articular disc repositioning and found that one year after surgery, patients who underwent disc repositioning presented with bone apposition in localized condylar regions. He concluded that articular disc repositioning seems to promote a protective function demonstrated by mild bone resorption at the anchor region and bone apposition at all other condylar surfaces¹.

Multiple techniques and systems such as the Mitek system[®] and Arthrex system (Arthrex Corkscrew[®]) have been described. MITEK anchors were first designed for orthopedic surgery. The MITEK mini anchor is a suitable size for TMJ disc stabilization, the performance of the anchor for TMJ disc repositioning has been assessed in different papers and has been successfully used in the management of internal derangement¹⁴. Its structure and composition contribute significantly to the osseointegration of the screw in the bone, assuring proper positioning of the TMJ disc, and long-term stability of the surgery.

Preoperatively, the indication for disc repositioning shall be confirmed by MRI, which can help define the relationship of the disc and condyle and its aspect, as well as discard

sings of perforation. MRI has gained wide acceptance in evaluating the TMJ with high accuracy in determining the articular disc position related to the condyle and articular eminence¹. MRI is as well recommended postoperatively to assess the position of disc. Since 2003, Yang and coworkers¹⁵ have used a self-inserting miniscrew anchor for disc repositioning since 2003, and the immediate repositioning rate was 96.3 % by MRI evaluation. Since 2011, Yang modified the technique¹⁶ to include complete release of the anterior disc attachments and overcorrection of the disc position. The short-term stability of this technique by MRI evaluation was 98.6 %.

He and colleagues¹⁷ reported their 5-year experience with disc repositioning in 61 patients (76 joints) and observed a success rate of 89 % as checked on postoperative MRI. Moreover, 89 % of these patients showed improvement in pain, range-of-motion, and had an appropriate disc-condyle relationship five years subsequent to the initial operation. MRI examination of the relapsed joints showed that relapse was associated to excessive fibrosis and scarring within the anterior recess and resorption of the anterior slope of the condyle due to foreshortening of the disc after repositioning surgery. Thus, they proposed that the anterior release shall be filled with subcutaneous fat harvested from the preauricular region to prevent relapse caused by fibrosis and scar contracture¹⁸. The last modification they proposed involved the design of the bone anchor. Most surgical anchors, including the Arthrex and Mitek anchors, cannot be removed, so they proposed utilizing a modified bone anchor that is a self-drilling screw with a slot on the end for the sutures.

Also, Sanromán et al.¹⁹ in 2000 evaluated 12 patients who underwent discopexy with the MITEK anchor, including postoperative MRI evaluation. They analyzed pain, TMJ noises, MIO improvement and jaw movements and found pain improvement with a statistically significant increase in the mean mouth opening range in their follow up (from 29.1 mm to 35.7 mm). However, they also report that the repositioned disc remained in place in 10 of 12 patients at one year follow up and persistent articular sounds in 8 of the 12 patients included. In the 6 months follow up MRI they found that 10 of the 12 discs were correctly repositioned, whilst 2 remained dislocated.

Furthermore, Zhou¹¹ found bone regeneration in 74.5 % (111 out of 149 joints) on MRI, especially young patients. They postulated that in a growing stage, the condyle may have growth ability after disc repositioning which could reduce facial deformities. Therefore,

they recommended that disc repositioning should be considered in patients as early as possible before the disc becomes severely deformed and shortened.

In our protocol, the indications for TMJ disc repositioning surgery included patients who referred pain and limited mouth opening and presented with anterior disc displacement (with or without reduction) that did not respond to, at least, 6 months of nonsurgical treatment and had preserved discs as observed on MRI (absence of perforation). In this study, we excluded patients who had undergone previous TMJ surgery.

Pain was referred by 92 % of patients preoperatively and decreased to 20 % after surgery. Preoperative pain was evaluated by the VAS scale with a mean value of 6,56 (Range [6-8]) which decreased to 2,40 after surgery (Range [0-5]), with a mean decrease of 4,16 points.

48 % of patients presented with preoperative clicking, which only decreased to 40 % after surgery. Preoperative mean maximum mouth opening was 29,28 mm, which increased to 36,08 mm at one-year postoperatively, meaning an increase of 6,8 mm, which was statistically significant ($p < 0,05$).

Our results are in line with those published in the literature. Overall, we found an improvement in pain and mean mouth opening range. Mouth opening range increased a total of 6,8 mm at the end of the follow up and pain decreased by 4,16 points in the VAS scale, with only a 20 % of patients referring pain at the end of the follow up. Nonetheless, the improvement in TMJ clicking was not so noted, in concordance with previous publications¹⁹. Hence, we believe that TMJ clicking may not be a reliable indicator of clinical improvement.

On MRI evaluation, we found that 23 of 30 discs were correctly positioned (76,66 %). There is a certain clinical-radiological discrepancy in our findings. We found that most patients improved in terms of pain and MIO and were satisfied with the results. Despite, 23,33 % of the discs were displaced on postoperative MRI. Hence, we highlight the importance of clinical evaluation of patients with TMD, both preoperatively and postoperatively. However, we also believe that further studies to analyze long-term (5 year) results and stability are needed.

As of limitations to this study, the number of patients is limited and could be increased. Also, as mentioned above, a longer-term follow-up report (5 year follow up) could be interesting to analyze long term stability of the discs and to see how many discs remain

in position after that time. Further investigation to shed light on possible reasons for the clinical-radiological discrepancy is needed.

CONCLUSIONS

The aim of disc repositioning is to improve mouth opening and decrease pain in patients with disc displacement who do not respond to conservative treatment or less invasive procedures. In this manner, we can prevent condylar resorption and joint degeneration. It shall be performed the earliest possible, especially in younger patients where surgery is more successful and even bone apposition has been reported. The MITEK mini anchor has proven to be a safe and reliable tool for disc repositioning. Pain was significantly reduced, and mouth opening increased considerably for these patients. Nonetheless, there is a doubtless discrepancy between clinical and radiological postoperative findings, remarking the importance of clinical over radiological evaluation of patients with TMD.

REFERENCES

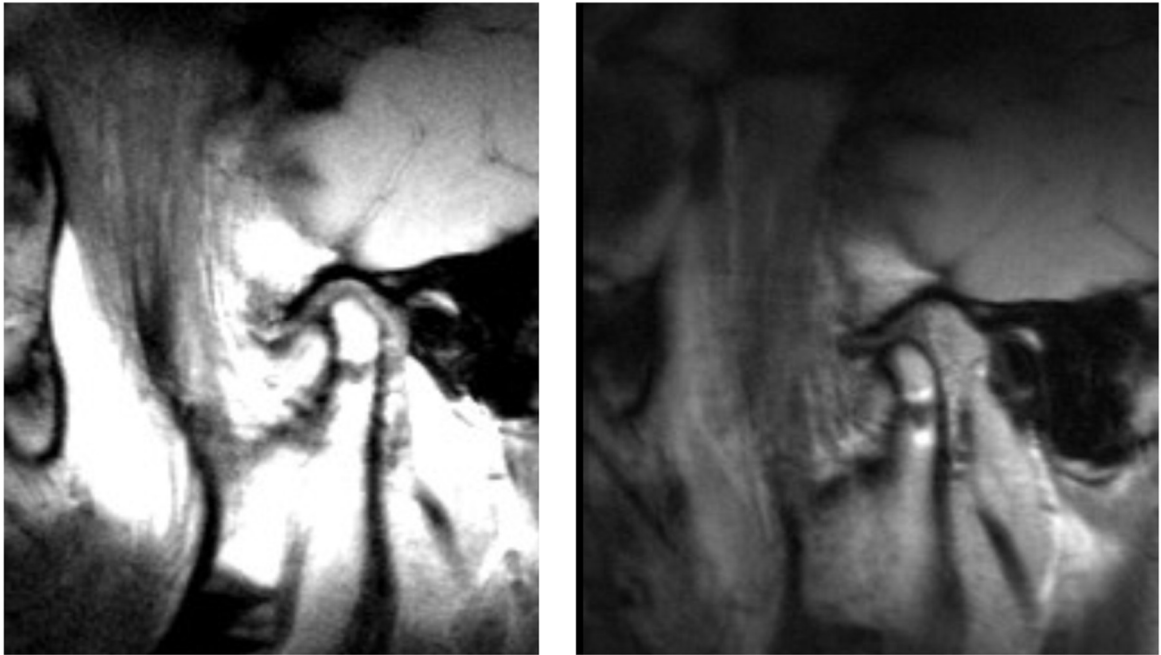
1. Gonçalves JR, Cassano DS, Rezende L, Wolford LM. Disc repositioning Does it really work? *Oral Maxillofacial Surg Clin N Am.* 2015;27(1):85-107.
2. He D, Yang C, Zhang S, Cai X, Wilson JJ. Modified temporomandibular joint disc repositioning with miniscrew anchor: part I--surgical technique. *J Oral Maxillofac Surg.* 2015;73(1):47.e1-9.
3. Mehra P, Wolford LM. The Mitek mini anchor for TMJ disc repositioning: surgical technique and results. *Int J Oral Maxillofac Surg.* 2001 Dec;30(6):497-503.
4. Annandale T. On displacement of the interarticular cartilage of the lower jaw and its treatment by operation. *Lancet.* 1887;1:411-2.
5. McCarty WL, Farrar WB. Surgery for internal derangements of the temporomandibular joint. *J Prosthet Dent.* 1979 Aug;42(2):191-6.
6. Wolford LM, Karras S, Mehra P. Concomitant temporo- mandibular joint and orthognathic surgery: a prelimi- nary report. *J Oral Maxillofac Surg.* 2002;60(4):356-62.

7. Perez D, Brown ZL, Amarista FJ, Pham M. Treatment of malocclusion after TMJ disc repositioning with MITEK anchors. A retrospective review. *J Stomatol Oral Maxillofac Surg.* 2019;120(6):540-4.
8. Martín-Granizo R, Millón-Cruz A. Discopexy using resorbable pins in temporomandibular joint arthroscopy: Clinical and magnetic resonance imaging medium-term results. *J Craniomaxillofac Surg.* 2016;44(4):479-86.
9. Muñoz-Guerra MF, Rodríguez-Campo FJ, Fernández-Domínguez M. The auricular cartilage graft used as interpositional material for disc replacement after failed TMJ operative arthroscopy. *J Stomatol Oral Maxillofac Surg.* 2018;119(4):328-36.
10. Roh HS, Kim W, Kim YK, Lee JY. Relationships between disk displacement, joint effusion, and degenerative changes of the TMJ in TMD patients based on MRI findings. *J Craniomaxillofac Surg.* 2012;40(3):283-6.
11. Zhou Q, Zhu H, He D, Yang C, Song X, Ellis III E. Modified Temporomandibular Joint Disc Repositioning With Mini-screw Anchor: Part II-Stability Evaluation by Magnetic Resonance Imaging. *J Oral Maxillofac Surg.* 2019;77(2):273-9.
12. Hu YK, Yang C, Xie QY. Changes in disc status in the reducing and nonreducing anterior disc displacement of temporomandibular joint: a longitudinal retrospective study. *Sci Rep.* 2016;6:34253.
13. Wolford LM, Cardenas L. Idiopathic condylar resorption: diagnosis, treatment protocol, and out-comes. *Am J Orthod Dentofacial Orthop* 1999; 116(6):667–77.
14. Ryba FM, Ali A, Matthews NS. Temporomandibular joint meniscopexy using the Arthrex Corkscrew® mini anchor system: technical note. *Br J Oral Maxillofac Surg.* 2015;53(3):299-300.
15. Zhang S, Liu X, Yang X, Yang C, Chen M, Haddad MS, et al. Temporomandibular joint disc repositioning using bone anchors: an immediate post surgical evaluation by magnetic resonance imaging. *BMC Musculoskelet Disord.* 2010;11:262.
16. Yang C. The relationship between temporomandibular joint disc displacement and condylar resorption and the comprehensive treatment protocol. *Chin J Stomatol.* 2017;52(3):157-60.
17. Cai XY, Jin JM, Yang C. Changes in disc position, disc length, and condylar height in the temporomandibular joint with anterior disc displacement: a longitudinal

- retrospective magnetic resonance imaging study. *J Oral Maxillofac Surg.* 2011;69(11):340-6.
18. He D, Yang C, Zhu H, Ellis E. Temporomandibular Joint Disc Repositioning by Suturing Through Open Incision: A Technical Note. *J Oral Maxillofac Surg.* 2018;76(5):948-54.
19. Fernandez Sanromán J, Sandoval Gutiérrez JL, Goizueta Adame C, Buscema C. Discoplasty with Mitek anchors for the treatment of the anterior disk displacement reduction of the TMJ: A prospective clinical study with MRI. *Rev Esp Cir Oral Maxillofac.* 2000;22:252-8.

Prepublicación

Figure 1. MRI evaluation of the disc before after surgery in the same patient. Images were evaluated in closed and open mouth in sagittal T2-weighted images.



Prepublica

Figure 2. Surgical pictures where the disc is released and the sutures are tied.

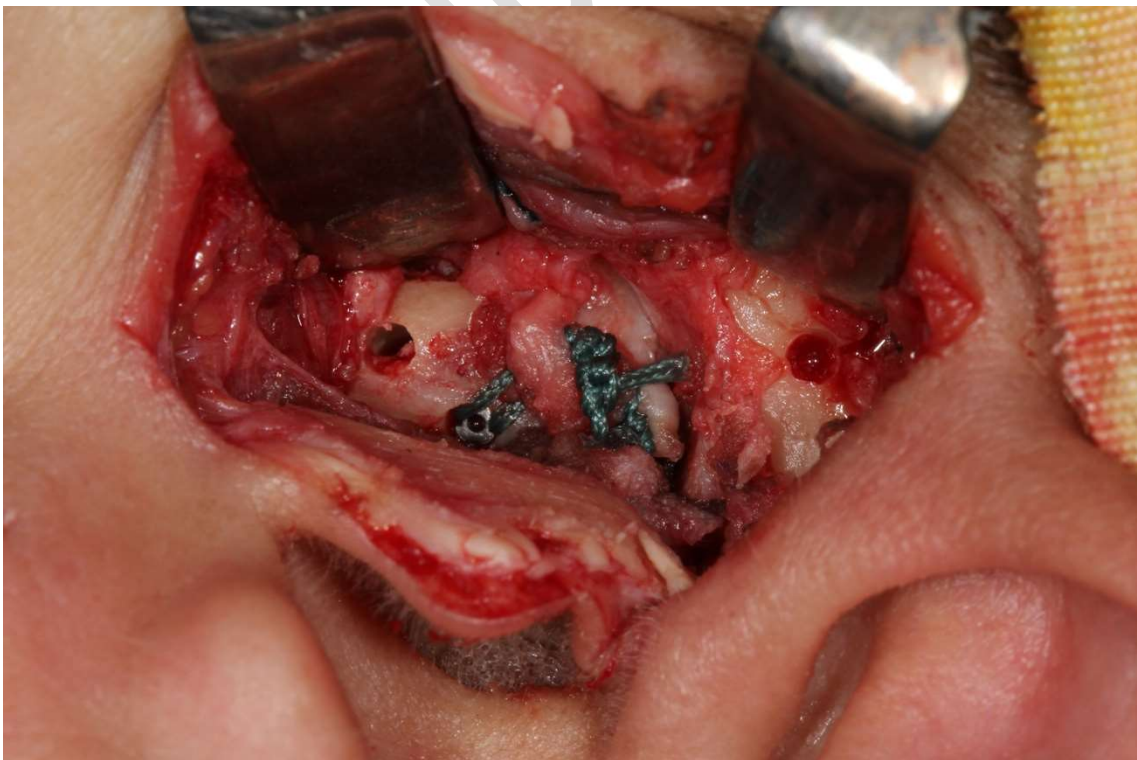
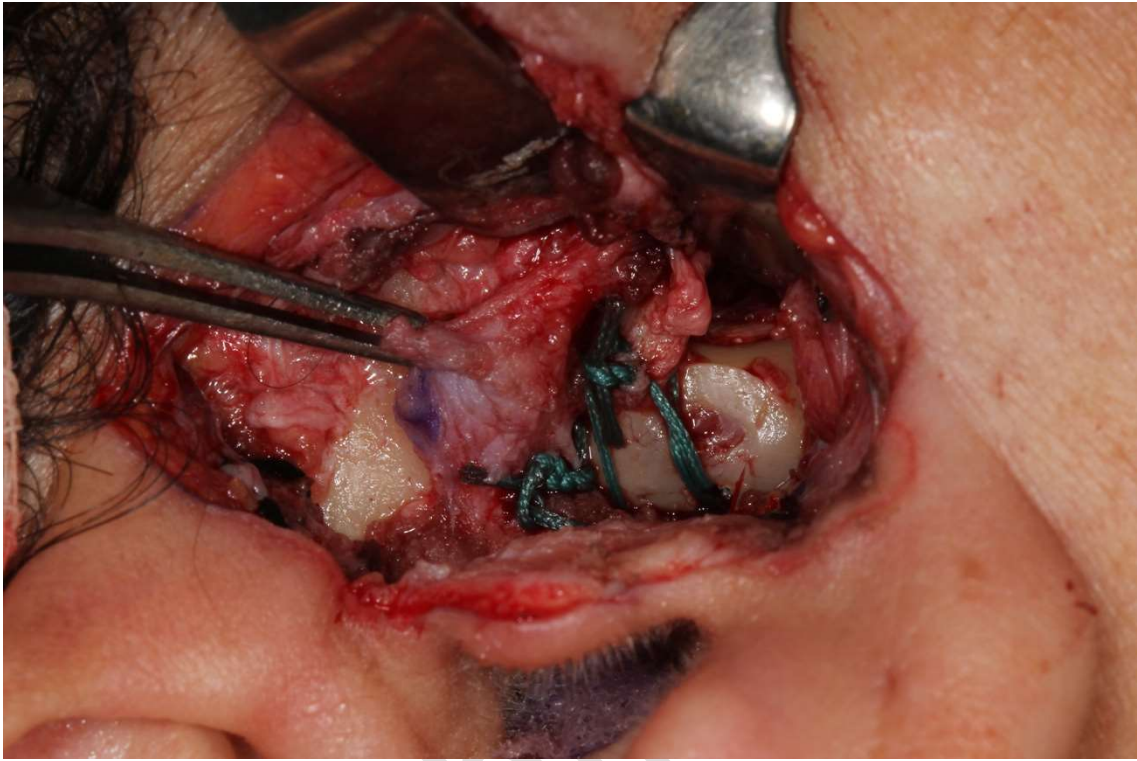


Figure 3. Comparison between preoperative and postoperative MIO (in mm), with a mean a increase of 6,8 mm at the enf of the follow up ($p < 0,05$).

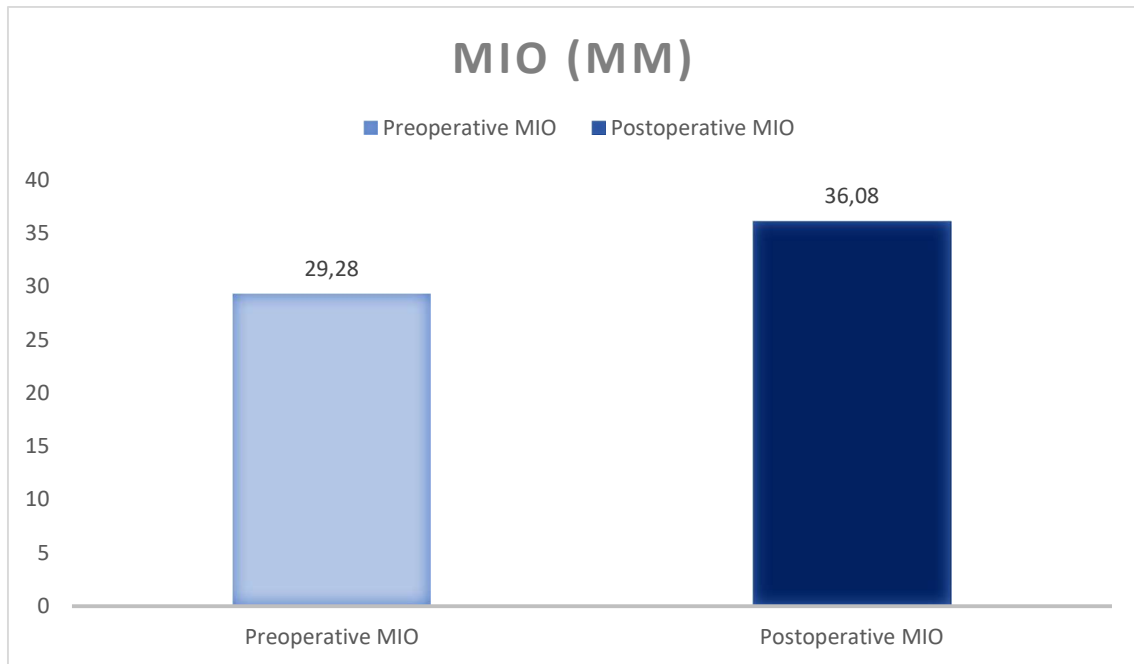


Figure 4. Preoperative and postoperative symptoms.

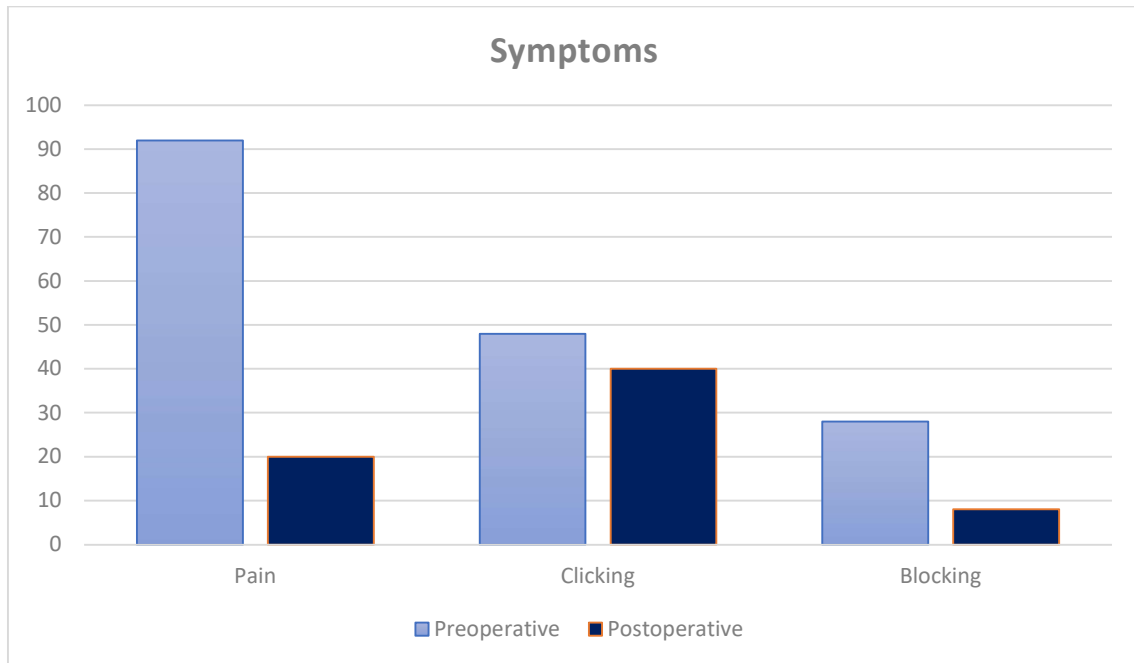


Figure 5. Mean VAS values before and 1 year after surgery. Pain as measured by the VAS scale decreased to 2,40 after surgery with a total decrease of 4,16 points.

