



# Revista Española de Cirugía Oral y Maxilofacial

Publicación Oficial de la SECOM CyC Sociedad Española de Cirugía Oral y Maxilofacial y de Cabeza y Cuello

## Artículo Aceptado para su pre-publicación / Article Accepted for pre-publication

### Título / Title:

Abordaje endoscópico en el tratamiento de las fracturas subcondíleas: nuestra experiencia / Endoscopic-assisted approach in the treatment of subcondylar fractures: our experience.

### Autores / Authors:

Marta Maria Pampin Martínez, Jose Luis del Castillo Pardo de Vera, Iñigo Aragón Niño, Juan Pablo Rodríguez Arias, Jose Luis Cebrián Carretero

DOI: [10.20986/recom.2022.1225/2020](https://doi.org/10.20986/recom.2022.1225/2020)

### Instrucciones de citación para el artículo / Citation instructions for the article:

Pampin Martínez Marta Maria, del Castillo Pardo de Vera Jose Luis, Aragón Niño Iñigo, Rodríguez Arias Juan Pablo, Cebrián Carretero Jose Luis. Abordaje endoscópico en el tratamiento de las fracturas subcondíleas: nuestra experiencia / Endoscopic-assisted approach in the treatment of subcondylar fractures: our experience.. j.maxilo 2022. doi: 10.20986/recom.2022.1225/2020.



Este es un archivo PDF de un manuscrito inédito que ha sido aceptado para su publicación en la *Revista Española de Cirugía Oral y Maxilofacial*. Como un servicio a nuestros clientes estamos proporcionando esta primera versión del manuscrito en estado de prepublicación. El manuscrito será sometido a la corrección de estilo final, composición y revisión de la prueba resultante antes de que se publique en su forma final. Tenga en cuenta que durante el proceso de producción se pueden dar errores, lo que podría afectar el contenido final. El copyright y todos los derechos legales que se aplican al artículo pertenecen a la *Revista Española de Cirugía Oral y Maxilofacial*.

## ENDOSCOPIC-ASSISTED APPROACH IN THE TREATMENT OF SUBCONDYLAR FRACTURES: OUR EXPERIENCE

### ABORDAJE ENDOSCÓPICO EN EL TRATAMIENTO DE LAS FRACTURAS SUBCONDÍLEAS: NUESTRA EXPERIENCIA

Marta María Pampín Martínez, José Luis del Castillo Pardo de Vera, Íñigo Aragón Niño, Juan Pablo Rodríguez Arias y José Luis Cebrián Carretero

*Servicio de Cirugía Oral y Maxilofacial. Universidad Hospital La Paz. Madrid, España*

#### CORRESPONDENCIA:

Marta María Pampín

[mpampin@ucm.es](mailto:mpampin@ucm.es)

Recibido: 14-11-2020

Aceptado: 17-03-2022

#### ABSTRACT

**Introduction:** The management of subcondylar fractures has been very controversial in the maxillofacial literature. The open reduction and internal fixation (ORIF) technique has been considered by many authors the gold standard in selected cases. However, with the rise in endoscopic techniques in the craniomaxillofacial area, new boundaries and less invasive techniques are being explored. The endoscopic approach of subcondylar fractures has proved overall good and similar results to open approaches whilst reducing complications such as facial nerve injury. In this article we purpose to describe our experience with the endoscopic approach to subcondylar fractures.

**Material and methods:** We retrospectively analyzed 11 patients with subcondylar fractures treated at our department via an endoscopic approach. The number and type of plates used in each patient is recorded. Results and complications observed for all patients are described as well as functional outcomes in terms of mouth opening at 1 week, 3 months and 6 months postoperatively.

**Results:** One patient presented with transient damage to the marginal and frontal branches of the facial nerve. 18,2 % of patients had their hardware removed due to pain or infection at the fracture site. No cases of salivary fistula or sialoceles were found in this study. Mean mouth opening at one week postoperatively was 31.8 mm which increased to 37.8 mm at 6 months after surgery, meaning an increase of 18,86 % through the follow-up. Also, 18,2 % of patients presented with persistent deviation with mouth opening and one patient presented with postoperative persistent malocclusion that was treated with IMF and elastics.

**Conclusion:** The endoscopic management of subcondylar fractures is a safe alternative to the open approach, specially in favorable cases, which reduces the risk of complications associated to open approaches, such as unfavorable scarring, salivary gland complications and facial nerve damage. In our series only one patient presented with transient damage to the facial nerve. 18.2 % of the plates were removed, which is a high percentage and should be evaluated, although the small size of the series should be taken into account. Maxillofacial surgeons should be encouraged to learn and trained in endoscopic techniques and include the endoscopic assisted approach in their surgical armamentarium.

**Keywords:** Subcondylar fractures, endoscopic approach.

## RESUMEN

**Introducción:** El manejo de las fracturas subcondíleas ha sido muy controvertido en la literatura maxilofacial. La técnica de reducción abierta y fijación interna (RAFI) ha sido considerada por muchos autores como el *gold standard* en casos seleccionados. Sin embargo, con el auge de las técnicas endoscópicas en el área craneomaxilofacial se han puesto en marcha técnicas menos invasivas. El abordaje endoscópico de las fracturas subcondíleas ha demostrado en general buenos resultados, similares a los abordajes abiertos, al mismo tiempo que reduce complicaciones como la lesión del nervio facial. En este artículo nos proponemos describir nuestra experiencia con el abordaje endoscópico de las fracturas subcondíleas.

**Material y métodos:** Analizamos retrospectivamente 11 pacientes con fracturas subcondíleas tratados en nuestro servicio mediante abordaje endoscópico. Se recoge el número y tipo de placas utilizadas en cada paciente. Se describen los resultados y las complicaciones observadas para todos los pacientes, así como los resultados funcionales en términos de apertura oral a la semana, 3 meses y 6 meses después de la intervención.

**Resultados:** Un paciente presentó lesión transitoria en las ramas marginal y frontal del nervio facial. Al 18,2 % de los pacientes se les retiraron las placas, por dolor o infección. En este estudio no se encontraron casos de fístula salival o sialocele. La apertura oral media a la semana del postoperatorio fue de 31,8 mm y aumentó a 37,8 mm a los 6 meses de la cirugía, lo que supuso un aumento del 18,86 % durante el seguimiento. Además, el 18,2 % de los pacientes presentó desviación persistente con la apertura de la boca y un paciente presentó maloclusión persistente postoperatoria que fue tratada con bloqueo intermaxilar y elásticos.

**Conclusión:** El manejo endoscópico de las fracturas subcondíleas es una alternativa segura al abordaje abierto, especialmente en casos favorables, lo que reduce el riesgo de complicaciones asociadas a los abordajes abiertos, como cicatrización desfavorable, complicaciones de las glándulas salivales y daño del nervio facial. En nuestra serie solo un paciente presentó daño transitorio del nervio facial. Un 18,2 % de las placas se retiraron, lo que es un porcentaje elevado y debe ser evaluado, aunque debe tenerse en cuenta el tamaño reducido de la serie. Se debe alentar a los cirujanos maxilofaciales a que aprendan y se capaciten en técnicas endoscópicas e incluyan el abordaje asistido por endoscopia en su armamento quirúrgico.

**Palabras clave:** Fracturas subcondíleas, abordaje endoscópico.

## INTRODUCTION

Condylar fractures account for more than a third of all mandibular fractures<sup>1</sup>. They are frequently associated to other mandibular fractures, most frequently those located in the parasymphysis and symphysis. Different classification systems have been described

and used in the literature; however, they are frequently divided in: *head* (diacapitular) fractures, *neck* fractures and *subcondylar* fractures.

The management of condylar fractures is highly controversial and depends on the level of fracture and displacement. There are two major treatment modalities: closed treatment and open reduction and internal fixation (ORIF)<sup>2</sup>. Closed treatment is more prone to suboptimal results in determined cases, particularly deviation with mouth opening, loss of height at the mandibular rami and malocclusion, alongside with a blind immobilization of the bone segments for a prolonged time, which can have implications in the dynamics of the temporomandibular joint and the risk of arthrosis<sup>3</sup>. Nonetheless, closed treatment can also be an acceptable option in cases where no displacement nor angulation is present.

Classically, Zide and Kent's criteria for open reduction of condylar fractures have been applied<sup>4</sup>. Later, Schneider *et al.* settled clearer indications for ORIF in their article and recommended ORIF in fractures with an angulation higher than 10° and a shortening of more than 2 mm<sup>5</sup>. Superior functional and aesthetical results can be achieved with ORIF if correctly indicated<sup>6,7</sup>. Occlusal and temporomandibular joint (TMJ) disorders are reduced significantly with ORIF when correctly indicated: 23 % after closed treatment vs. 9 % after surgical treatment<sup>8</sup>.

ORIF has classically been performed through different approaches: the preauricular approach, the rhitidectomy approach and the retromandibular approach. All these approaches have proven to be useful but are not exempt of risks: salivary fistula, damage to the branches of the facial nerve and visible and unesthetic scars<sup>9</sup>.

In the last decades, the endoscopic management of low condylar fractures arose as a new treatment modality with promising results, avoiding unsightly scars and lowering the risk of facial nerve damage, avoiding the most feared complications associated to ORIF. However, endoscopic repair of condylar fractures has not routinely been used: training and specific equipment are required.

In this article we retrospectively analyzed patients with subcondylar fractures treated by an endoscopic-assisted transoral approach (EA-ORIF) in our department. We describe and discuss results and complications for this group of patients.

## **MATERIALS AND METHODS**

From January 2015 to January 2019 a total of 11 patients with subcondylar fractures who had been treated via EA-ORIF were consecutively selected. Preoperative CT and radiographies were taken for all patients, following our standard protocol. Both unilateral and bilateral fractures were included. Patients with associated mandibular fractures and other facial fractures were also included. Demographic data for this group was recorded. This study was approved by the Ethics Committee of our Hospital (CEIm). Patients suitable for open surgery were evaluated for endoscopic-assisted compliance. Patients who presented with fractures with more than 45° of medial deviation, fractures with more than 5mm of overlap, high condylar fractures, patients with open fractures, patients with panfacial fractures, patients who could not undergo a long operating time and patients with a history of fracture longer than 14 days were discarded for undergoing endoscopic methods. Fractures that did not satisfy these criteria were treated via an open approach and were not included in this study.

A postoperative orthopantomography was taken on the first postoperative day and follow up was performed at 1 week postoperatively, 4 weeks, 3 months and 6 months. Follow up included an orthopantomography at three and 6 months to evaluate reduction and bone healing. Patients were evaluated for pain, maximum interincisal opening and the presence of deviation, TMJ clicking, lateral extrusion and malocclusion. Also, shortening of the mandibular rami was evaluated clinically and in radiographs. Surgery was performed by the same senior surgeon, trained in endoscopic approaches and arthroscopy of the temporomandibular joint. We used a 4mm 30° endoscope. Surgery was performed under general anesthesia and nasotracheal intubation. An intraoral incision was placed over the external oblique line in a standard fashion and an optical subperiosteal cavity was created. Then, the 30° endoscope was inserted and the fractures were inspected. Reduction was then accomplished by manipulating the teeth or distracting the mandible downwards in the angle region. Once adequately reduced the premorbid occlusion was established and intermaxillary fixation with screws and wires was performed. Then, fixation was performed assisted by a right-angle screwdriver/drill (Figures 1 and 2). Osteosynthesis was performed using different plating methods: 2 linear 2.0 4-hole miniplates, trapezoidal plates and delta plates

After surgery, patients were instructed in oral hygiene and a soft diet was indicated for 4 weeks. Intermaxillary fixation with elastic bands was applied for one week, and then patients initiated physiotherapy and exercises.

For all patients, number and type of plates were recorded. Results in terms of mouth opening and complications were registered and compared.

## RESULTS

A total of 11 patients were included: 2 women (18,18 %) and 9 men (81,82 %). The median age for these patients was 41 years. Only 1 patient (9,09 %), patient number 5, presented with a bilateral subcondylar fracture, and EA-ORIF was decided in one of the fractures, whilst the other fracture, which was non-displaced, was treated via closed treatment with IMF and a soft diet. The remaining 10 patients (90,91 %) had unilateral fractures. The most common etiology was interpersonal violence (6 patients, 63,63 %) and traffic accidents (3 patients, 27,27 %). A total of 5 patients (45,45 %) presented with accompanying mandibular fractures, being the parasymphysis the most common location.

Most patients received a 2 linear plate osteosynthesis (5 patients) (Figure 3) or a delta plate (Figure 4) (4 patients). Two patients (18,18 %) received a trapezoidal plate.

Complications are presented in Table I for all patients. One patient (9,09 %), patient number 1, suffered transient damage to the marginal and frontal branches of the facial nerve, which resolved uneventfully within 6 months. No cases of salivary fistula or sialoceles were found in this study. Also, no complications related to the surgical wound or scarring were found.

Regarding hardware complications, two of these patients, patients number 3 and 6, (18,18 %) had their plates removed. The first patient, patient number 3, was treated with a trapezoidal plate and had it removed one month postoperatively due to infection at the fracture site. The patient required antibiotic treatment for 1 week (amoxicilline-clavulanic acid 875/125 mg) and the plate was removed. The patient was treated conservatively with a soft diet. The second patient with hardware complications, patient number 6, had been treated with 2 linear 2.0 mm plates and both were removed one year later due to complaints and pain at the surgical site. Nonetheless, no signs of

infection or pseudoarthrosis were observed. He did not show misalignment on postoperative radiographs and neither did he refer malocclusion or TMJ symptoms. The remaining nine patients had no complications associated to the hardware.

Mean mouth opening at one week postoperatively was 31.8 mm with a standard deviation (SD) of 2.75. At three months postoperatively, it increased to 35.6 mm with a SD of 1.50. At the 6-month follow-up, the mean mouth opening was 37.8 with a SD of 1.12 (Figure 5). This meant an increase of 18,86 % at the longest follow-up.

Mild deviation with mouth opening was noted in all patients at the end of first postoperative week. This is a common finding during the first days after surgical treatment of subcondylar fractures. By 3 months postoperatively, only two patients (18,18 %), patients 8 and 11, presented with persistent deviation with mouth opening that persisted at the longest follow-up. No TMJ symptoms were reported for these patients regarding clicking and blocking. All patients received intermaxillary fixation (IMF) and elastics for one week postoperatively. Only one patient (9,09 %), patient 10, reported malocclusion after this period and was treated with further IMF for 3 weeks. None of the 11 patients had the endoscopic approach converted to open surgery. No intraoperative complications were reported either.

## **DISCUSSION**

The treatment of condylar fractures has been an arduous topic of debate and has significantly changed in the last century. They can be managed both via conservative treatment or by open reduction and internal fixation (ORIF)<sup>10,11</sup>. Traditionally, the majority of condylar process fractures have been managed with closed techniques, typically with maxillomandibular fixation and elastics<sup>12</sup>. However, no anatomical reduction can be accomplished, and worse functional and aesthetic results were described and soon ORIF became the gold standard technique in cases of angulation or displacement. Restoring the adequate anatomy of the condyle and enabling immediate normal function are the main advantages of the ORIF approach<sup>13</sup>.

So far there is a lack of consensus and an endless debate regarding the management of subcondylar fractures<sup>13</sup>. In general, absolute indications for ORIF of condylar fractures include displacement into the middle cranial fossa, failure to obtain dental occlusion via



closed reduction, lateral extracapsular displacement of the condyle, presence of a foreign body, or an open fracture with potential for fibrosis<sup>14</sup>.

Different surgical approaches exist for ORIF<sup>15</sup>, however they carry a risk of facial nerve damage, salivary fistula, sialocele, scarring, etc. Later, the intraoral approach for subcondylar fractures was described, with the aim to avoid the aforementioned complications associated to ORIF. The first case series of condylar fractures managed via an intraoral approach were reported by Lee in 1998<sup>16,17</sup>, who used this approach assisted by a transbuccal trocar. Schon<sup>18</sup> stated that intraoral approaches are better suited for condylar fractures with lateral over-ride and undisplaced or minimally displaced fractures.

In 1998, Jacobovicz<sup>19</sup> described the endoscopic assisted approach to condylar fractures with the aim to reduce complications and combine the best of both closed and open treatment<sup>8,20</sup>. The current literature states that with this approach, risk of facial nerve injury is significantly reduced as well as scarring, since this procedure is performed through an intraoral incision, showing advantages over both open and closed treatments. However, it is technically demanding and requires training and specific equipment. It should not be indicated in all condylar fractures and shall not be considered in cases with medial override, high condylar neck fractures and large angulation, panfacial fractures and open fractures. Also, some authors report worse reduction of the fracture due to the difficulties in handling and the reduced surgical field, with higher rates of hardware failure and nonunion.

Lee et al. reported a large series of subcondylar fractures treated via endoscopic-assisted approach, treating a total of 22 fractures with overall good functional and aesthetic results<sup>16</sup>. Later<sup>17</sup>, he would report his experience with 40 fractures treated endoscopically. In this latter article, he reported one case of transient facial paralysis and 3 cases of hardware fracture, with a median maximum mouth opening of 43 mm at 8 weeks postoperatively, reporting good occlusion and good alignment. Nogami et al.<sup>21</sup> studied 30 patients treated either via an extraoral retromandibular approach or an intraoral endoscopic approach using right-angled instruments. In the ORIF group, 7 patients had transient facial paralysis, while no cases of facial paralysis were found in the EA ORIF group. TMJ symptoms were similar for both groups, however, median mouth opening 1 month postoperatively was higher in the open approach compared to

the endoscopic approach (35.7 mm vs. 28.4 mm), with comparable results at 6 months postoperatively.

Creo et al.<sup>3</sup> reported their experience in the endoscopic-assisted management of condylar fractures in 26 patients. They reported adequate alignment in 80,8 % of fractures, with a mean maximum interincisal opening (MIO) of 35 mm at 4 weeks postoperatively. In our study, we did not report MIO at one month, but at 3 months it was 35.6 mm. They found good occlusion and no cases of mandibular height loss nor open bite, similarly to our results. However, they found no cases of facial paralysis or hardware failure were described in their article. In our study we found one case of transient facial nerve damage (9,09 %) and two cases of hardware removal (18,18 %). They described one case with persistent lateral deviation and one case of surgical site infection that required drainage, but the hardware was not removed. In our study we found two patients with persistent lateral deviation at 3 months postoperatively (18,18 %). They concluded that the intraoral endoscopic-assisted approach in condylar fractures is a safe, reproducible and efficient technique in most extracapsular fractures and insist on including this technique in the armamentarium of the maxillofacial surgeon.

Frenkel et al.<sup>13</sup> also analyzed their results in the treatment of condylar fractures via an endoscopic-assisted approach in 12 patients. Mean time for EA-ORIF in their report was 180 minutes, achieving stable occlusion in all patients and a significant improvement in maximum mouth opening (45mm) 6 months postoperatively.

Goizueta et al.<sup>9</sup> reported their experience in 53 patients (55 fractures) treated of condylar fractures via EA-ORIF. Mean surgical time was 184,5 min (85-465), quite similar to that of Frenkel et al.<sup>13</sup>. They found overall satisfactory radiological reduction in 92 % of the fractures, similar to our results (90,9 %). A total of ten patients presented with intraoperative or postoperative complications (18,8 %). Three patients presented with temporal paralysis of the frontal branch (5,6 %), two patients required myorelaxant treatment and five patients required occlusal adjustments. Four patients (7,5 %) were reoperated.

Existing literature on EA-ORIF of subcondylar fractures suggest that this modality has comparable functional results in terms of MIO and masticatory and joint function. Furthermore, the risk of complications such as facial nerve damage, salivary gland

fistula, sialoceles and unsightly scars are significantly reduced. Despite, the main drawbacks of EA-ORIF include its steep learning curve and the need for special equipment and training. Another alleged drawback of this technique is the extended operating time, which has been reported to decrease with surgeon's experience. Frenkel<sup>13</sup> found a significant decrease in operating time after the 5th operation.

In our study, most patients received a 2 linear plate osteosynthesis 45,45 % and 36,36 % received a delta plate. Both types of osteosynthesis are acceptable in the treatment of subcondylar fractures. Generally, we would decide between one or another depending on the space available for plate placement and the fracture line: if difficulties are found for the placement of two plates, then a 3D type of plate such as the delta plate would be preferred. This is one of the main disadvantages of EA-ORIF, since many surgeons would feel reluctant to this approach due to the limited surgical and visual field, as well as the difficulties in handling the instruments and positioning the plates and screws.

We found two cases (18,18 %) where the plates were removed. This is an elevated percentage and a comparative study between ORIF and EA-ORIF regarding hardware removal rates would be interesting. A possible explanation is that the approach for EA-ORIF was performed via an intraoral approach, and this may lead to higher rates of infection and contamination of the plate. However, it should be considered that the number of patients is limited, and a broader series is needed to confirm this hypothesis. Mild deviation with mouth opening was noted in all patients at the end of first postoperative week. This is a common finding in the first days after treatment of subcondylar fractures. By 3 months postoperatively 18,18 % of patients presented with persistent deviation with mouth opening that persisted at the longest follow-up, which is a reported complication in subcondylar fractures. However, these patients were satisfied with the results and this deviation did not interfere with jaw function. On the other hand, no TMJ symptoms such as clicking, or blocking were reported by these patients at the longest follow up. We believe that physiotherapy and early jaw exercises are of utmost importance to avoid future TMJ problems in these patients. Only one patient presented with malocclusion that required IMF for a longer period of time, with good results. No signs of malocclusion were found for the rest of patients.

We found 1 case of transient facial paralysis in our study group (9,09 %) which resolved satisfactorily within 6 months. This complication has been reported by other authors<sup>9,17</sup> and it is believed that is provoked by the distension of tissues created in the optical cavity for handling and manipulation of instruments. No cases of salivary fistula or sialoceles were found in this study, similarly to previous publications<sup>3,9,21</sup>. Also, no complications related to the surgical wound or scarring were found.

We report similar MIO improvement to previous authors<sup>3,21</sup>, being 31.8 mm at one week after surgery and increasing to 35.6 mm by 3 months and 37.8 by 6 months postoperatively with a mean increase of 18,86 % at the longest follow-up.

Regarding limitations to this study, the number of patients is small and limited and could be increased, so these results should be considered cautiously. The main drawback of EA-ORIF is the difficulty that resides in the technique and surgical field, which is limited. Therefore, we think that for future publications, mean surgery time should be recorded and analyzed, similar to other publications<sup>9,1</sup>.

Also, this study lacks control group, and therefore a proper comparison to ORIF could not be made. We believe that a prospective comparative study with an open approach (ORIF) cohort could be interesting in order to compare functional outcomes and complications for both groups as well as total operative time for further conclusions.

## **CONCLUSION**

Transient damage to the facial nerve is diminished but not completely avoided with EA-ORIF, as we found one patient who presented with transient damage to the facial nerve. We report no complications related to the parotid gland or scarring were found. Also, we found two cases of hardware removal (18,18 % of patients). We believe further studies to compare this rate and other complications to the ORIF approach are needed. For the rest of patients, no hardware complications or signs of malocclusion were found. No TMJ complications were reported as well at the longest follow-up.

EA-ORIF is a safe and acceptable alternative to ORIF in subcondylar fractures. However, adequate equipment and intensive training is required for proper management and optimal results, as well as proper patient selection.

## DISCLOSURE

There are no conflicts of interest to declare.

## REFERENCES

1. Ellis 3<sup>rd</sup> E, Moos KF, el-Attar A. Ten years of mandibular fractures: an analysis of 2,137 cases. *Oral Surg Oral Med Oral Pathol.* 1985;59(2):120-9. DOI: 10.1016/0030-4220(85)90002-7.
2. Leiser Y, Peled M, Braun R, Abu-El Naaj I. Treatment of low subcondylar fractures – a 5-year retrospective study. *Int J Oral Maxillofac Surg.* 2013;42(6):716-20. DOI: 10.1016/j.ijom.2013.03.006.
3. Creo Martinez T, Nuñez Vera MV, Tofé Povedano A, Rodríguez Ruiz JA. Tratamiento de las fracturas subcondíleas y de cuello de cóndilo mandibular mediante abordaje intraoral endoscópicamente asistido. *Rev Esp Cir Oral Maxilofac.* 2019;41(2):75-9. DOI: 10.20986/recom.2019.1033/2019 DOI: 10.20986/recom.2019.1033/2019.
4. Zide MF. Open reduction of mandibular condyle fractures. Indications and technique. *Clin Plast Surg.* 1989;16(1):69-76. DOI: 10.1016/S0094-1298(20)31368-7.
5. Schneider M, Erasmus F, Gerlach KL, Kuhlisch E, Loukota RA, Rasse M. Open reduction and internal fixation versus closed treatment and mandibulomaxillary fixation of fractures of the mandibular condylar process: A randomized, prospective, multicenter study with special evaluation of fracture level. *J Oral Maxillofac Surg.* 2008;66(12):2537-44. DOI: 10.1016/j.joms.2008.06.107.
6. Throckmorton GS, Ellis 3<sup>rd</sup> E, Hayasaki H. Masticatory motion after surgical or nonsurgical treatment for unilateral fractures of the mandibular condylar process. *J Oral Maxillofac Surg.* 2004;62(2):127-38. DOI: 10.1016/j.joms.2003.01.003.
7. Brandt MT, Haug RH. Open versus closed reduction of adult mandibular condyle fractures: a review of the literature regarding the evolution of current thoughts on management. *J Oral Maxillofac Surg.* 2003;61(11):1324-32. DOI: 10.1016/S0278-2391(03)00735-3.

8. Eckelt U. Commentary regarding the publication. Fractures of the mandibular condyle—a review of 466 cases. *J Craniomaxillofac Surg.* 2006;34(7):433-44. DOI: 10.1016/j.jcms.2006.07.855.
9. Goizueta-Adame CC, Pastor-Zuazaga D, Agüero de Dios E, Sebastian Lopez C. Osteosíntesis intraoral asistida por endoscopia en las fracturas del proceso condilar de la mandíbula: revisión de 53 casos. *Rev Esp Cir Oral Maxilofac.* 2012;34(4):156-65. DOI: 10.1016/j.maxilo.2012.02.002. DOI: 10.1016/j.maxilo.2012.02.002.
10. Akdag O, Yildiran G, Abaci M, Tosun Z. Endoscopic-Assisted Treatment Combined With Transoral and Transbuccal Approach to Mandibular Subcondylar Fractures. *J Oral Maxillofac Surg.* 2018;76(4):831.e1-831.e5. DOI: 10.1016/j.joms.2017.11.034.
11. Gokcan MK, Kucuk B, Yazicioglu D. Four hands technique in transoral endoscope-assisted fixation of condyle fractures. *J Otolaryngol Head Neck Surg.* 2010;39(4):442-7.
12. Forrest CR. Application of minimal-access techniques in lag screw fixation of fractures of the anterior mandible. *Plastic Reconstr Surg.* 1999;104(7):2127-34. DOI: 10.1097/00006534-199912000-00028.
13. Frenkel B, Abu Shqara F, Berg T, Rachmiel A. Endoscopically Assisted Open Reduction and Internal Fixation of Sub-Condylar Fractures: Debunking Some of the Myths. *J Craniofac Surg.* 2020;31(6):1727-30. DOI: 10.1097/SCS.00000000000006480.
14. Stacey DH, Doyle JF, Mount DL, et al. Management of mandible fractures. *Plast Reconstr Surg.* 2006;117(3):48-60. DOI: 10.1097/01.prs.0000209392.85221.0b.
15. Handschel J, Rugeberg T, Depprich R, Schwarz F, Meyer U, Kübler NR, et al: Comparison of various approaches for the treatment of fractures of the mandibular condylar process. *J Craniomaxillofac Surg.* 2012;40(8):397-401. DOI: 10.1016/j.jcms.2012.02.012.
16. Lee C, Mueller RV, Lee K, Mathes SJ. Endoscopic subcondylar repair. Functional, aesthetic and radiographic outcomes. *Plast Reconstr Surg.* 1998;102(5):1434-43. DOI: 10.1097/00006534-199810000-00016.

17. Lee C, Stiebel M, Young DM. Cranial nerve VII region of the traumatized facial skeleton: Optimizing fracture repair with the endoscope. *J Trauma*. 2000;48(3):423-31. DOI: 10.1097/00005373-200003000-00009.
18. Schön R, Fakler O, Gellrich NC, Schmelzeisen R. Five-year experience with the transoral endoscopically assisted treatment of displaced condylar mandible fractures. *Plast Reconstr Surg*. 2005;116(01):44-50. DOI: 10.1097/01.PRS.0000169690.78547.0C.
19. Jacobovicz J, Lee C, Trabulsky PP. Endoscopic repair of mandibular subcondylar fractures. *Plast Reconstr Surg*. 1998;101(2):437-41. DOI: 10.1097/00006534-199802000-00030.
20. Hackenberg B, Lee C, Caterson EJ. Management of subcondylar mandible fractures in the adult patient. *J Craniofac Surg*. 2014;25(1):166-71. DOI: 10.1097/SCS.0000000000000498.
21. Nogami S, Takahashi T, Yamauchi K, Miyamoto I, Kaneuji T, Yamamoto N, et al. Clinical comparison between the retromandibular approach for reduction and fixation and endoscope-assisted open reduction and internal fixation for mandibular condyle fractures. *J Craniofac Surg*. 2012;23(6):1815-8. DOI: 10.1097/SCS.0b013e3182710393.

**Figure 1. Once adequate reduction of the fracture is achieved, the plate is fixated using a right-angled screwdriver.**

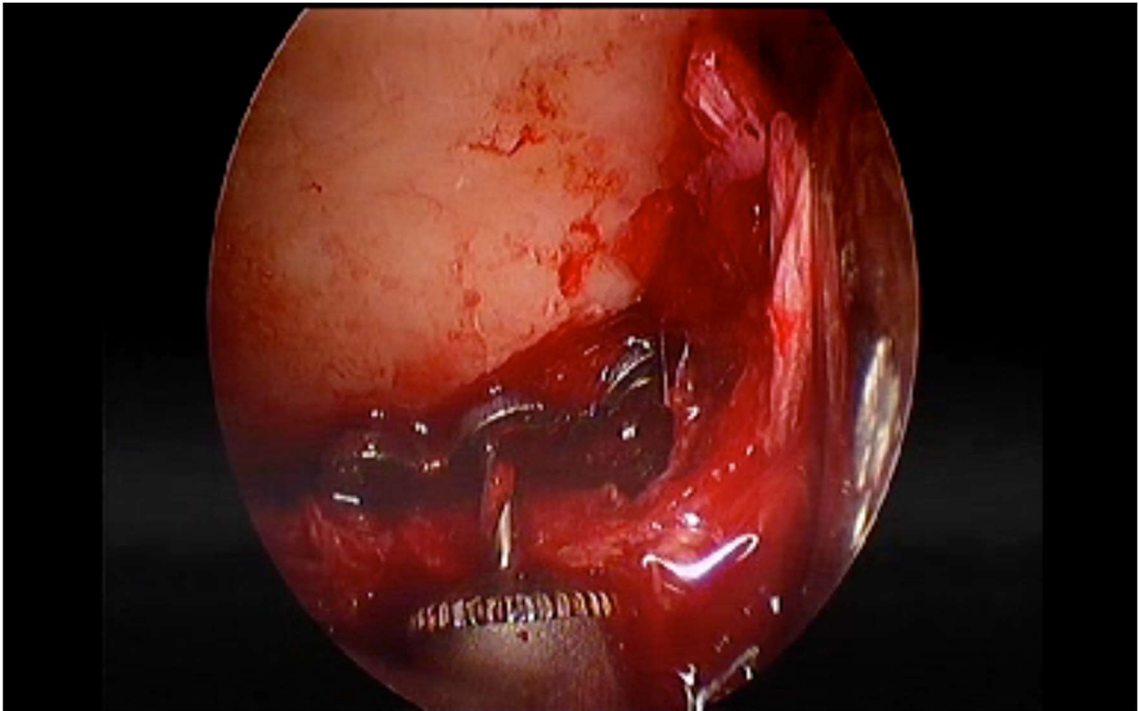
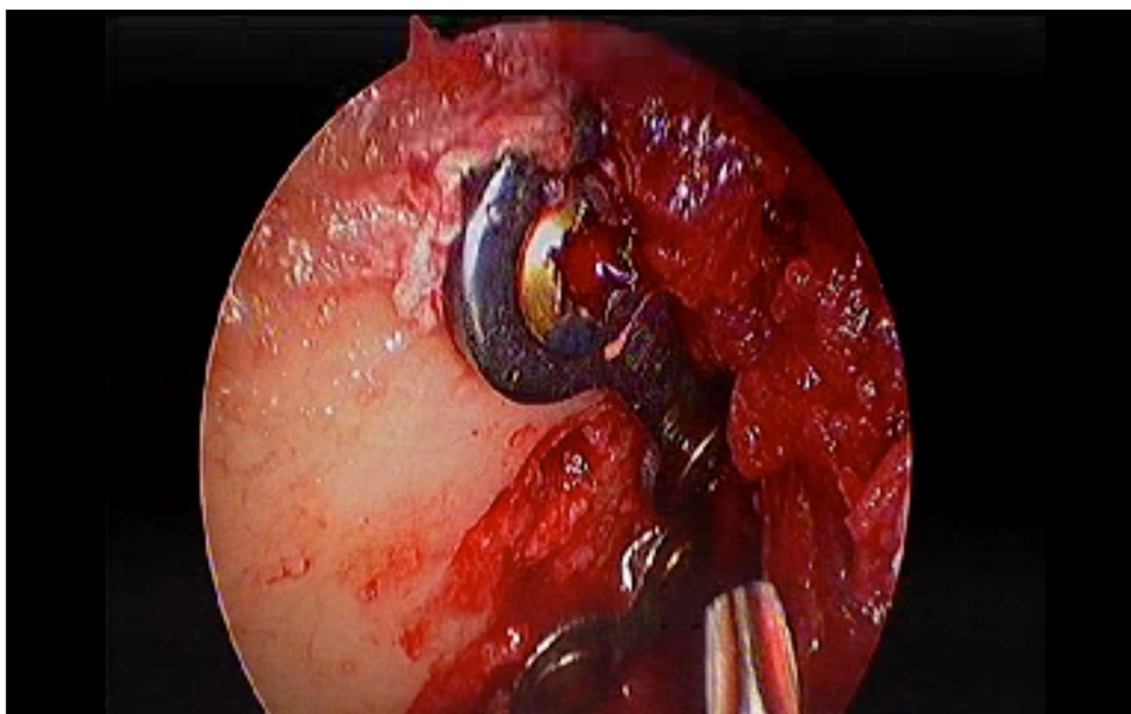


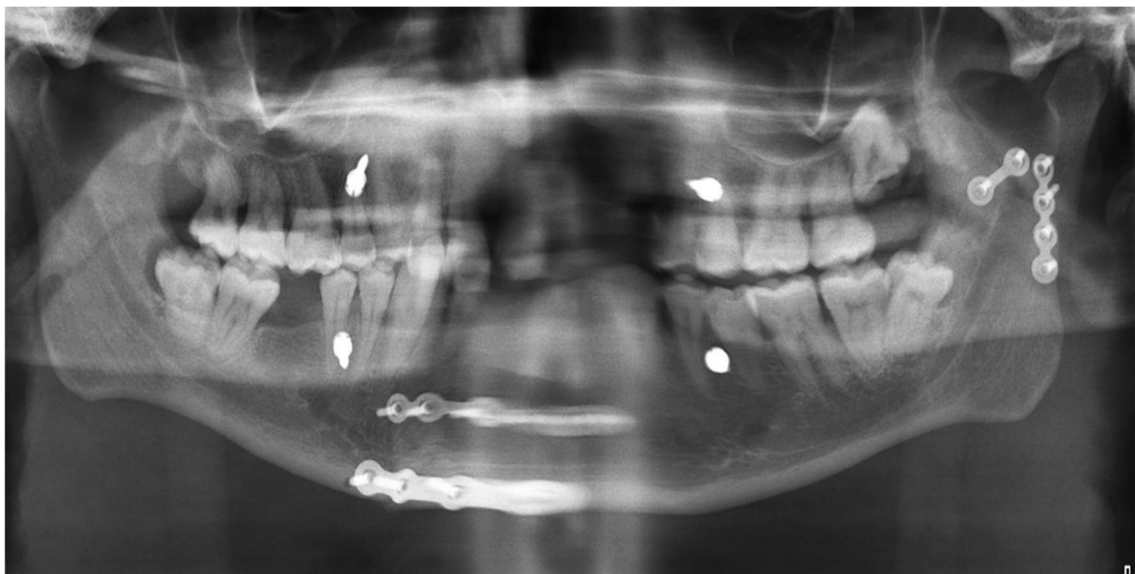


Figure 2. Plate fixated.



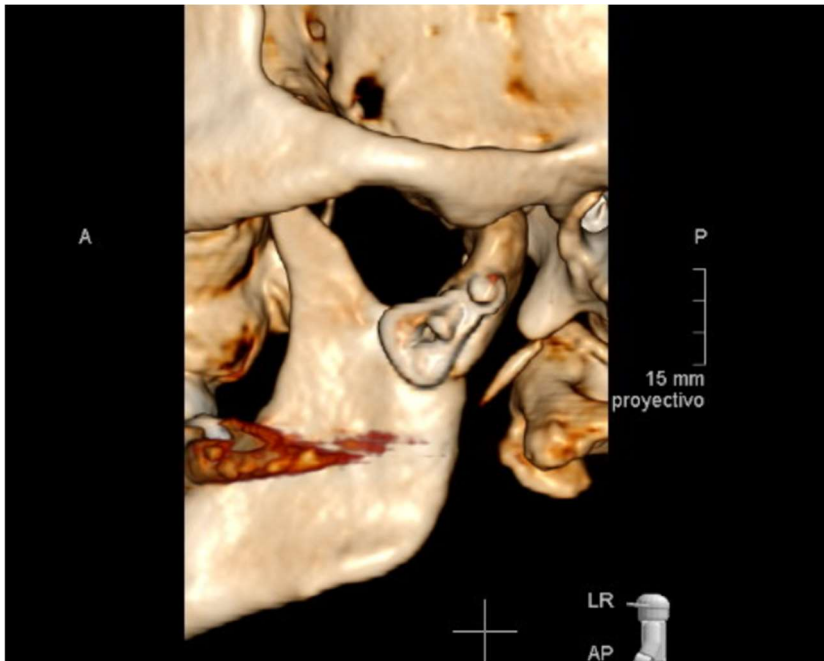
Prepubl

**Figure 3. A postoperative radiograph showing a left subcondylar fracture treated with 2 linear plates via EA-ORIF.**



Prepublico

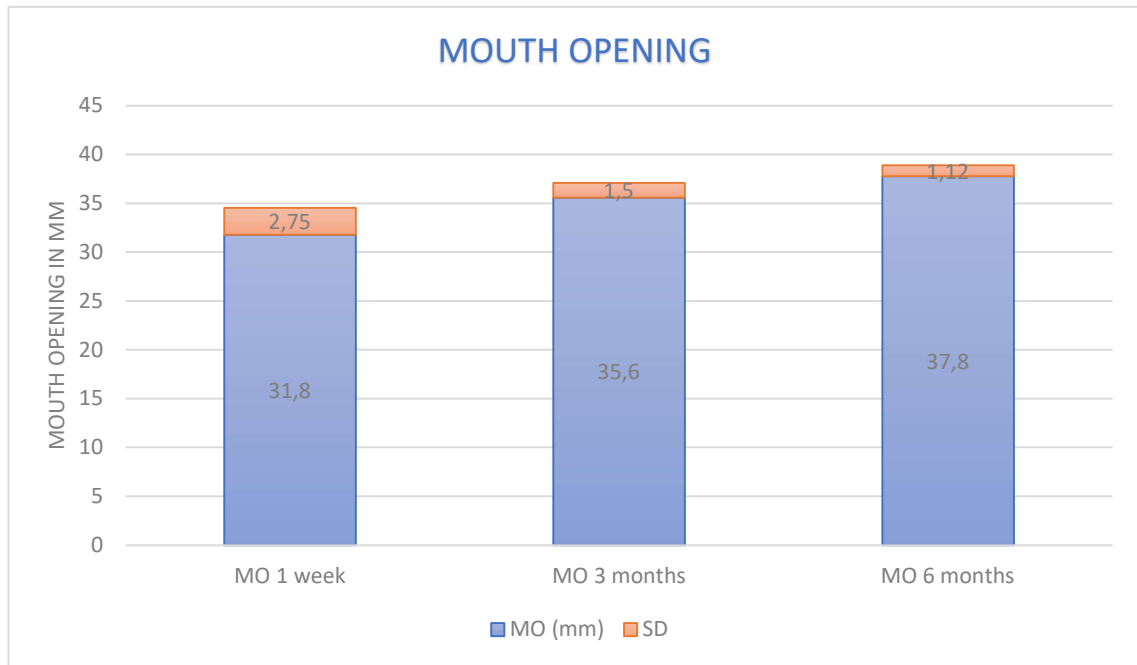
Figure 4. Left condylar fracture treated with a delta plate via EA-ORIF.



**Table I. Patients included in the study.**

PATIENT	Sex	N.º fractures	Other fractures	Type of osteosynthesis	Complications
Patient 1	F	1	Yes	2 linear plates	Transient facial paralysis frontal and marginal branches
Patient 2	M	1	No	2 linear plates	
Patient 3	M	1	Yes	1 trapezoidal plate	Infection at fracture site, plate was removed 1 month postoperatively and treated conservatively (soft diet)
Patient 4	F	1	No	1 delta plate	
Patient 5	M	2	Yes	2 linear plates	Only one of the fractures was treated via endoscopic approach, the other fracture was treated with IMF and soft diet
Patient 6	M	1	No	2 linear plates	Plates removed 1 year postoperatively due to pain
Patient 7	M	1	No	1 delta plate	
Patient 8	M	1	No	1 trapezoidal plate	Persistent deviation
Patient 9	M	1	Yes	1 delta plate	
Patient 10	M	1	No	1 delta plate	Persistent malocclusion, treated with IMF for 3 weeks
Patient 11	M	1	Yes	2 linear plates	Persistent deviation

**Figure 5. Mouth opening at 1 week postoperatively, 3 months postoperatively and 6 months postoperatively.**



Prepub