

RECONSTRUCTION OF COMPOSITE FACIAL DEFECTS: NASAL SIDEWALL AND MEDIAL CHEEK. THE IMPORTANCE OF TWO FLAPS TECHNIQUE

RECONSTRUCCIÓN DE DEFECTOS FACIALES COMPLEJOS: PARED LATERAL NASAL Y MEJILLA MEDIA. LA IMPORTANCIA DE LOS COLGAJOS INDEPENDIENTES

Celia Sánchez Gallego-Albertos, Pedro Muñoz Losa, José Luis Cebrián Carretero y Miguel Burgueño García

Departament of Maxillofacial Surgery, Hospital Universitario La Paz, Madrid, Spain

CORRESPONDENCIA:

Celia Sánchez Gallego-Albertos

celiasga22@gmail.com

Recibido el 31 de marzo de 2020

Aceptado el 7 de junio de 2020

ABSTRACT

Facial skin defects affecting the nasal sidewall and medial cheek entail a reconstructive challenge for the surgeon. They belong to the central third of the face and thus, they have a direct impact on aesthetics. The difficulty in repairing these defects lies in the need to restore facial symmetry and three-dimensionality. In addition, there is a need to preserve the qualities of the skin of each subunit, since they have a different dermal thickness and different number of sebaceous glands. That is the reason why these defects should not be addressed using a single flap and they require a different reconstructive approach. Although composite central facial defects are common, there is not a unified approach to repair them. The cases presented in this manuscript involves patients who underwent surgical intervention to remove a skin cancer. The extirpation resulted in a cutaneous defect affecting both the nasal sidewall and medial cheek. The surgical technique consisted of harvesting two different flaps, obtaining good cosmetic and functional results, and minimizing donor site morbidity.

Keywords: Facial subunits, aesthetic subunits, nasal sidewall, medial cheek, facial reconstruction, composite facial defect, two flaps.

RESUMEN

Los defectos cutáneos faciales que afectan a la pared lateral nasal y a la mejilla medial suponen un desafío reconstructivo para el cirujano. Pertenecen al tercio central de la cara y, por lo tanto, tienen un impacto directo en la estética. La dificultad para reparar estos defectos radica en la necesidad de restaurar la simetría facial y la tridimensionalidad. Además, es necesario preservar las cualidades de la piel de cada subunidad, ya que tienen un grosor dérmico diferente y una cantidad diferente de glándulas sebáceas. Por este motivo, estos defectos no deben abordarse con un solo colgajo y requieren un enfoque reconstructivo diferente. Aunque los defectos faciales centrales compuestos son comunes, no existe un enfoque unificado para repararlos. Presentamos varios casos clínicos de pacientes que fueron sometidos a extirpación de tumores cutáneos resultando en un defecto que afectaba a ambas subunidades mencionadas. La técnica quirúrgica consistió en reconstruir el defecto con dos colgajos diferentes, obteniendo buenos resultados cosméticos y funcionales y minimizando la morbilidad del sitio donante.

Palabras clave: Subunidades faciales, subunidades estéticas, pared lateral nasal, mejilla medial, reconstrucción facial, defecto facial compuesto, dos colgajos.

INTRODUCTION

The multiple aesthetic subunits of the face are defined by the natural mobility of the facial muscles, as well as by the skin colour, texture, thickness, facial planes, concavity, and convexity¹⁻⁶. The geography of the central face includes many anatomic units and its component subunits, which are essential to define an individual face⁴. Defects affecting more than one facial subunit are quite common and may represent a reconstructive challenge, but there is not a unified approach to repair them⁴.

Nasal sidewall and medial cheek are two adjacent subunits with specific differences between them. Trying to restore a composite defect involving these subunits with a single flap may be the first instinct, but this is rarely the best option¹⁻⁶. Doing so can lead us to obtain a bulky flap which has no similarity to the skin of the defect's site. Considering this, the reconstruction of a defect affecting nasal sidewall and medial cheek subunits requires a carefully planned reconstruction of each of the subunits. We report two cases to show the outcomes after reconstructing composite facial defects affecting both nasal sidewall and medial cheek by using different flaps for each subunit. Informed consent of each patient was obtained.

CLINICAL CASES

The first case presented is a 90-year-old woman who presented with a big, ulcerated lesion affecting both the nasal sidewall and the medial cheek, and even the inferior eyelid of the right eye (Figure 1). The histological analysis confirmed a squamous cell carcinoma moderately differentiated. An enhanced cervicofacial CT scan was performed to determine extension and discard cervical disease. The CT scan did not show cervicofacial nodal involvement and then surgery was performed.

A conservative approach was decided, preserving the right eye due to the age, comorbidities, and fragility of the patient. The extirpation of the tumour resulted in a big cutaneous defect affecting the right nasal sidewall, the right medial cheek, and the inferior eyelid of the right eye (Figure 1). An inverse facial advancement flap was harvested, elevated and advanced to cover the cheek and the inferior eyelid, and a glabellar flap was harvested, elevated, and rotated to cover the nasal defect (Figure 2). A lateral and medial canthopexy were also performed.

The surgical results after one week are shown (Figure 2). The follow up after 6 months showed good cosmetic and functional results, as the patient preserved a good eyelid competence despite the small right eyelid retraction. No adjuvant therapy was considered. No revision surgery was needed.

The second case is a 70 year-old-man who presented a recurrence of a basal cell skin cancer previously irradiated. The lesion was ill defined and affected the medial cheek and the nasal sidewall (Figure 3).

The reconstruction of this defect presented a challenge due to the extension, location, and fragility of the irradiated soft tissues. The CT scan showed invasion of the anterior wall of the maxillary sinus. No nodal involvement was found.

The surgical technique consisted in the tumour extirpation, including the anterior wall of the maxillary sinus (Figure 3). For the reconstruction, a glabellar flap was harvested, elevated, and rotated to cover the nasal defect, and a V-Y advancement flap of the right nasogenian area to cover the cheek (Figure 4). No reconstruction of the anterior sinus wall was performed, but in the postoperative period some depression of the area was detected and an infiltration of autologous fat from the abdominal area was performed. After 6 months he presented good cosmetic and functional results (Figure 4). He remained free of disease after 2 years of follow up.

DISCUSSION

Aesthetic principles and donor-site morbidity should be considered in the reconstruction of facial defects^{1,2}. This is particularly relevant in composite defects involving nasal sidewall and medial cheek. The nasal sidewall is a combination of convex and concave elements extending laterally from the dorsum to the junction of the nose with the medial cheek. The medial cheek joins the nose in an advancing slope into the nasal sidewall. Nasal skin differs histologically from every facial subunit, and specially from the cheek, as it has a significantly thicker dermal tissue and a higher amount of sebaceous glands⁷. Nasal skin is thin and limp in the rhinion area and becomes thicker caudally, as it adheres to the deep planes. When defects of the medial cheek extend onto the nasal sidewall, a single posteriorly or anteriorly based rotation advancement flap may lead to blunting of the nasofacial sulcus^{2,4,5}. For this reason it may be necessary to repair the nasal portion with a separate flap. These rules of central subunit reconstruction ensure similar skin quality and scars at the periphery of subunits so that they are hidden in the joins between them. Furthermore, this approach draws on centripetal wound contraction to establish a convex subunit contour. Our aim in the present manuscript was to restore the normal facial appearance by using two different flaps to reconstruct these defects. The glabellar flap is an option for nasal reconstruction, broadly described in the literature⁸, which offers excellent colour,

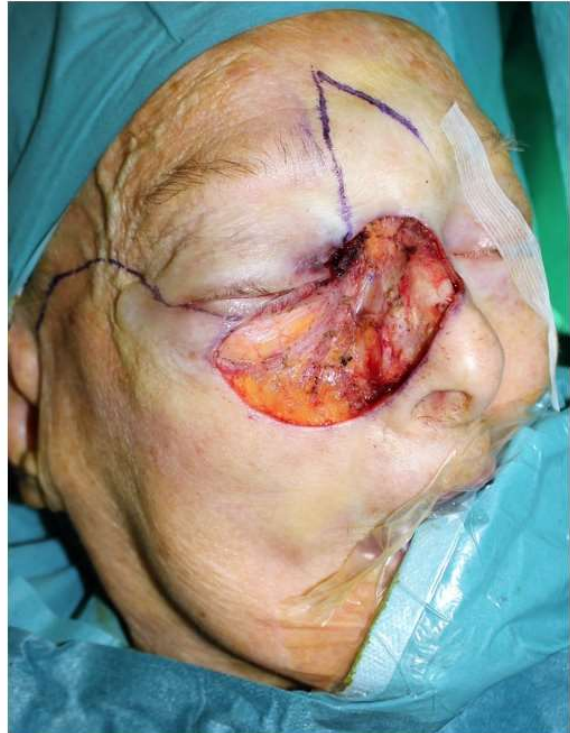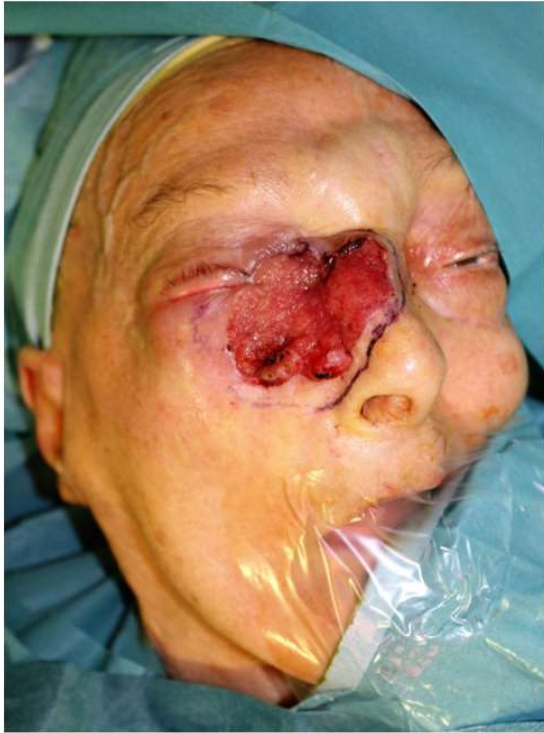texture, and volume match to restore nasal sidewall defects. The restoration of the medial cheek can be achieved by many different reconstruction techniques. Bernstein⁹ performs a two-flap technique to address a composite medial cheek and nasal sidewall defect by removing a small Burow's triangle at the ala-cheek junction and then advancing the cheek to the nasofacial sulcus, and a transposition nasal flap to cover the nasal defect. Kim et al.¹⁰ performs a cheek advancement with two Burrow's triangles and covers the nasal defect with a skin graft. Suárez et al.¹¹ performs a bilateral nasolabial V-Y island flaps combined with a glabella V-Y island flap to complete the 'like-for-like' subunit reconstruction after excision of a disfiguring xantelasma that extended from canthus to canthus through the nasal bridge. In the series of Rohrich et al.¹² a complex wound of nasal dorsum, sidewalls, medial cheeks, ala, tip, and partial columella is presented. They addressed the medial cheek defects with bilateral cheek advancement flaps and the dorsum, sidewalls, ala, tip, and anterior columellar defects were covered with a large forehead flap. We believe that preserving or recreating the nasofacial sulcus as an essential feature of the normal-appearing nose is mandatory to achieve a good cosmetic result. Rossi et al.¹³ develop a single flap reconstruction with an advancement cheek flap for the reconstruction of postoncological extended nasal sidewall defects, with good aesthetic results. Nevertheless, in our experience this type of single flap reconstruction for this type of defects leads to better results in some selected patients with soft tissue excess at the level of the nasofacial union. This study has some limitations, as the ideas are based on theoretical concepts, with the preliminary experience of some cases, obtaining good results. In our experience, the use of separate flaps to reconstruct these composite facial defects allowed to obtain very pleasant *like with like* results.

REFERENCES

1. Burget G, Menick F. The Subunit Principle in Nasal Reconstruction. *Plast Reconstr Surg.* 1985;76(2):239-47. DOI: 10.1097/00006534-198508000-00010.
2. Singh D, Bartlett S. Aesthetic Considerations in Nasal Reconstruction, and the Role of Modified Nasal Subunits. *Plast Reconstr Surg.* 2003;111(2):639-48. Doi: 10.1097/01.PRS.0000041602.85239.93.

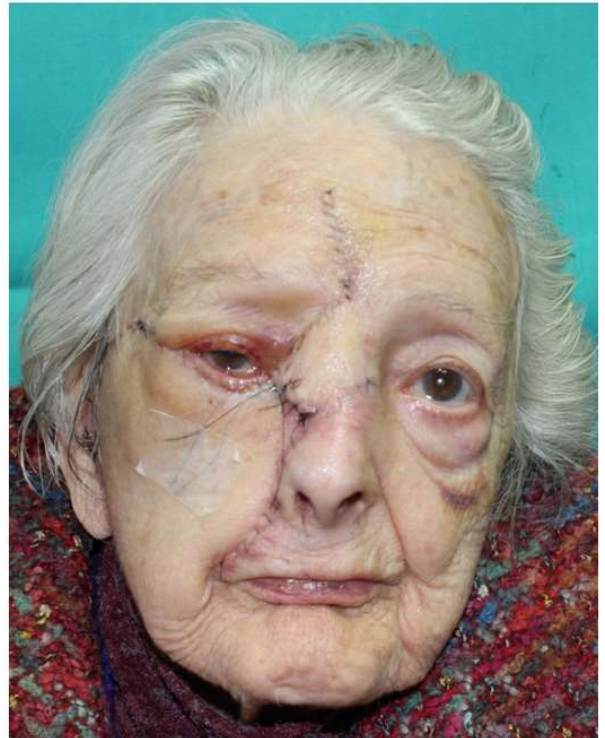
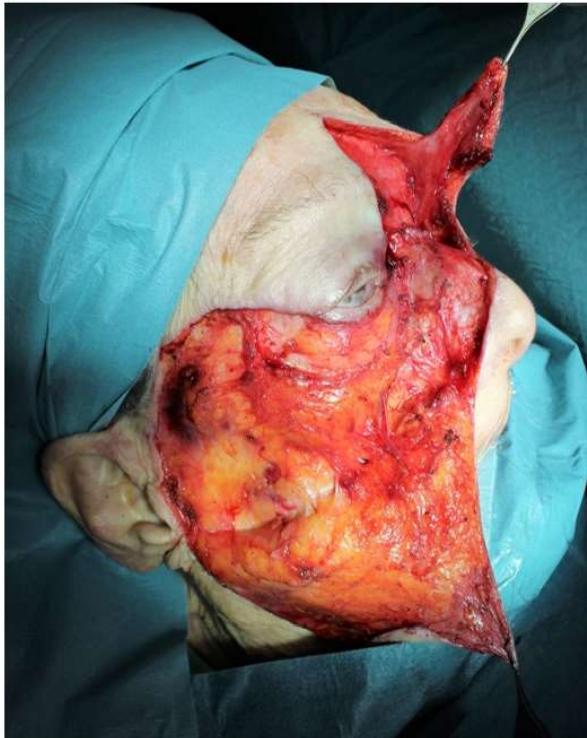
3. Menick F. Defects of the Nose, Lip, and Cheek: Rebuilding the Composite Defect. *Plast Reconstr Surg.* 2007;120(4):887-98. DOI: 10.1097/01.prs.0000277662.51022.1d.
4. Ratner D, Levender M. Reconstructing Complex Central Facial Defects Involving Multiple Cosmetic Subunits. *Facial Plast Surg.* 2013;29(05):394-401. DOI: 10.1055/s-0033-1353380.
5. Menick F. Reconstruction of the Cheek. *Plastic and Reconstructive Surgery.* 2001;108(2):496-504. DOI: 10.1097/00006534-200108000-00033.
6. Menick F. Complex Nasal Reconstruction: A Case Study: Composite Defect. *Facial Plast Surg Clin North Am.* 2011;19(1):197-211. DOI: 10.1016/j.fsc.2010.10.008.
7. Rahman M, Jefferson N, Stewart D, Oliver R, Walsh W, Gianoutsos M. The histology of facial aesthetic subunits: Implications for common nasal reconstructive procedures. *J Plast Reconstr Aesthet Surg.* 2010;63(5):753-6. DOI: 10.1016/j.bjps.2009.02.066.
8. Koch C, Archibald D, Friedman O. Glabellar Flaps in Nasal Reconstruction. *Facial Plast Surg Clin North Am.* 2011;19(1):113-22. DOI: 10.1016/j.fsc.2010.10.003.
9. Brodland 0044. Repair of the Left Nasal Sidewall, Nasofacial Sulcus, and Medial Cheek. *Dermatol Surg.* 2001;27(5):505-7. DOI: 10.1046/j.1524-4725.2001.01028.x.
10. Kim K, Gross V, Jaffe A, Herbst A. The Use of the Melolabial Burow's Graft in the Reconstruction of Combination Nasal Sidewall–Cheek Defects. *Dermatol Surg.* 2004;30(2):205-7. DOI: 10.1111/j.1524-4725.2004.30064.x.
11. Suárez J, Sadigh P, Jeng S. Aesthetic Subunit Reconstruction Facilitated with V-Y Island Advancement Flaps on the Face. *Plast Reconst Surg Glob Open.* 2014;2(5):e148. DOI: 10.1097/GOX.000000000000107.
12. Rohrich R, Griffin J, Ansari M, Beran S, Potter J. Nasal Reconstruction-Beyond Aesthetic Subunits: A 15-Year Review of 1334 Cases. *Plast Reconstr Surg.* 2004;114(6):1405-16. DOI: 10.1097/01.prs.0000138596.57393.05.
13. Rossi M, Milia A, Carmisciano M, D'Arpa S, Cordova A, Moschella F. Advancement Perforator Cheek Flap for Aesthetic One-Stage Reconstruction of Postoncological Extended Split-Thickness Defects of the Nasal Sidewall. *ScientificWorldJournal.* 2013;2013:169208. DOI: 10.1155/2013/169208.

Figure 1. A big, ulcerated lesion affecting both the nasal sidewall and the medial cheek, and even the inferior eyelid of the right eye (left). After the extirpation, we faced to a big cutaneous defect affecting both the nasal sidewall and medial cheek. Design of the flaps is shown (right).



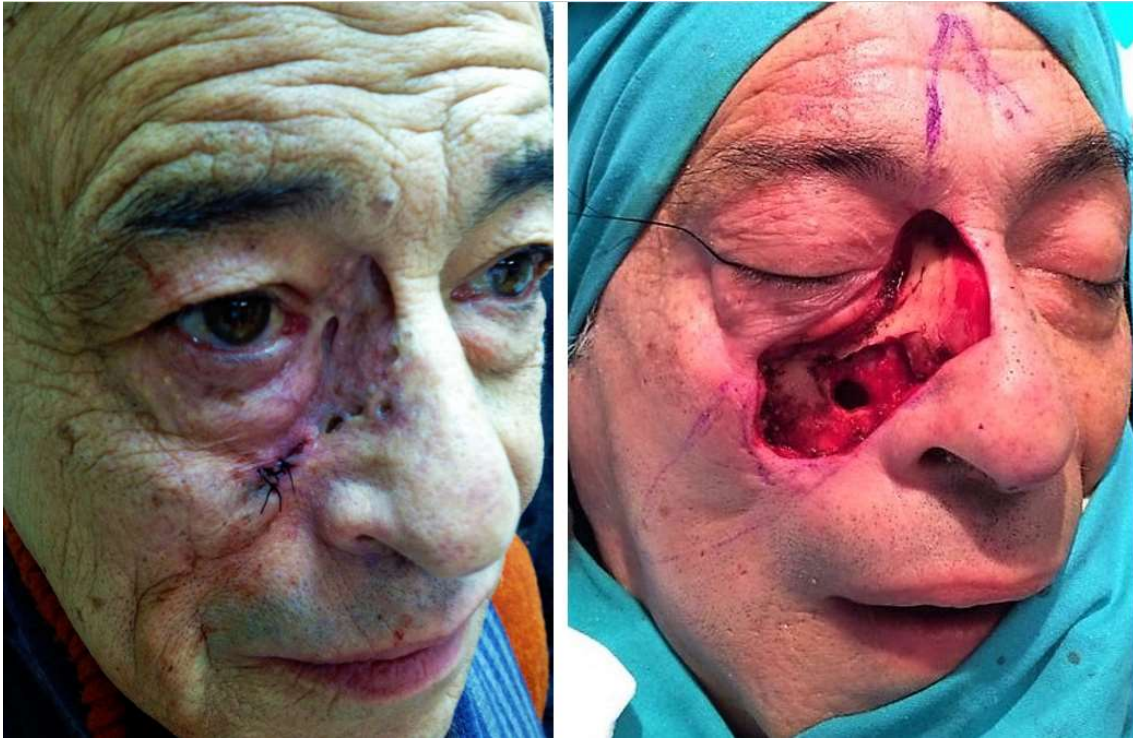Prepub

Figure 2. Harvesting of an inverse facial advancement for the cheek and the lower eyelid and a glabellar flap for the nose (left). Results after 1 week (right).



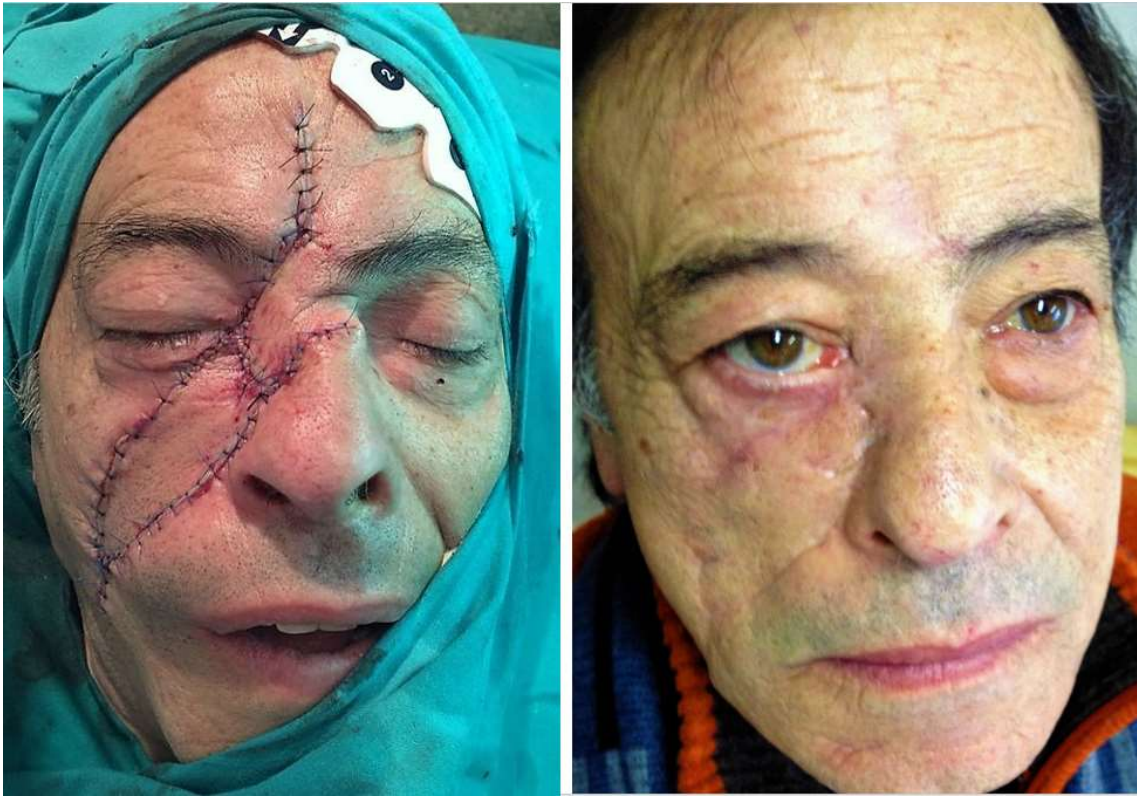Prepub

Figure 3. Recurrence of a basal cell skin cancer previously irradiated, affecting both medial cheek and nasal sidewall (left). Defect after removal of the skin tumour and the anterior wall of the maxillary sinus (right).



Prepu

Figure 4. Reconstruction with a glabellar flap and a V-Y advancement flap (left). Results after 6 months of follow up (right).



Prepub