



Artículo Aceptado para su pre-publicación / Article Accepted for pre-publication

Título / Title:

Un caso raro de una entidad descrita recientemente: carcinoma secretorio análogo mamario (CSAM) de la glándula parótida / A rare case of a recently described entity: mammary analogue secretory carcinoma (MASC) of the parotid gland

Autores / Authors:

Frederico Martins, Ana Marques, Tiago Neto, Rui Balhau

DOI: [10.20986/recom.2020.1066/2019](https://doi.org/10.20986/recom.2020.1066/2019)

Instrucciones de citación para el artículo / Citation instructions for the article:

Martins Frederico , Marques Ana, Neto Tiago, Balhau Rui. Un caso raro de una entidad descrita recientemente: carcinoma secretorio análogo mamario (CSAM) de la glándula parótida / A rare case of a recently described entity: mammary analogue secretory carcinoma (MASC) of the parotid gland. *j.maxilo* 2020. doi: 10.20986/recom.2020.1066/2019.



Este es un archivo PDF de un manuscrito inédito que ha sido aceptado para su publicación en la *Revista Española de Cirugía Oral y Maxilofacial*. Como un servicio a nuestros clientes estamos proporcionando esta primera versión del manuscrito en estado de prepublicación. El manuscrito será sometido a la corrección de estilo final, composición y revisión de la prueba resultante antes de que se publique en su forma final. Tenga en cuenta que durante el proceso de producción se pueden dar errores, lo que podría afectar el contenido final. El copyright y todos los derechos legales que se aplican al artículo pertenecen a la *Revista Española de Cirugía Oral y Maxilofacial*.

A RARE CASE OF A RECENTLY DESCRIBED ENTITY: MAMMARY ANALOGUE SECRETORY CARCINOMA (MASC) OF THE PAROTID GLAND

UN CASO RARO DE UNA ENTIDAD DESCRITA RECIENTEMENTE: CARCINOMA SECRETORIO ANÁLOGO MAMARIO (CSAM) DE LA GLÁNDULA PARÓTIDA

Frederico Martins¹, Tiago Neto¹, Ana Marques² y Rui Balhau¹

¹Maxillo-Facial Surgery Department, Centro Hospitalar e Universitário de São João. Porto, Portugal. ²Pathology Department, Centro Hospitalar e Universitário de São João. Porto, Portugal

CORRESPONDENCE:

Fredecirco Martins

Fredericocruzmartins@gmail.com

Received: 29-04-2019

Accepted: 11-09-2019

ABSTRACT

MASC is a salivary gland tumour which shares histological, immunologic and genetic characteristics with mammary secretory carcinoma including an ETV6 translocation and immunocytochemical positivity for S-100 protein, CK7, and mammaglobin as well as negativity for DOG1. This is a rare tumour with uncommon characteristics when compared to other salivary gland tumours. The case reported here is of a 28-year-old female patient who presented in the ER due to a palpable mass in the left parotid region. She underwent a superficial parotidectomy with using a mini-lifting approach, with tumour resection, followed by radiotherapy. The identified tumour shared most of the clinical characteristics with other cases of MASC described in the literature.

Keywords: MASC, mammary analogue secretory carcinoma, secretory carcinoma, salivary glands.

RESUMEN

CSAM es un tumor de glándula salival que comparte características histológicas, inmunológicas y genéticas con el carcinoma secretor mamario, que incluye una translocación ETV6 y positividad inmunocitoquímica para la proteína S-100, CK7 y mamaglobina, así como negatividad para DOG1. Este es un tumor raro con características poco comunes en comparación con otros tumores de glándulas salivales. El caso reportado aquí es el de una paciente de 28 años de edad que se presentó en la sala de emergencias debido a una masa palpable en la región parotídea izquierda. Se sometió a una parotidectomía superficial con un abordaje de mini-lifting, con resección tumoral, seguida de radioterapia. El tumor identificado compartía la mayoría de las características clínicas con otros casos de CSAM descritos en la literatura.

Palabras clave: CSAM, carcinoma secretorio análogo mamario, carcinoma secretorio, glándulas salivales.

INTRODUCTION

MASC is a low-grade malignant salivary gland cancer, first described by Alena Skálová in 2010¹, with various similarities to the secretory carcinoma of the breast including histology, immunohistochemistry and a genetic translocation².

Epidemiologically, it is usually encountered in adults with a mean age of 46 years-old³ and a slight male predominance^{3,4}. There have been 11 cases described in the paediatric population⁵.

There are three main differential diagnosis: AciCC which is positive for DOG1, does not have the ETV6-NTRK3 fusion gene and has basophilic granularity in the cytoplasm as an hallmark^{2,3}; mucoepidermoid carcinoma which is positive for p63 and is usually negative for S100 and mamaglobin in addition to having, in most cases, a t(11;19) translocation³ and, low-grade cribriform cystadenocarcinoma which has epithelial structures surrounded by an intact layer of p63 positive myoepithelial cells².

MASC is usually found in the parotid gland^{3,4} followed by the oral cavity and submandibular gland³. The most common presentation is of a slowly growing painless nodule². In most cases it has good prognosis and an indolent course⁴. High grade transformation followed by an accelerated clinical course with poor prognosis has been described^{3,4}.

CLINICAL CASE

Our case is of a 28-year-old women with no relevant past medical history who presented in the ER with a week old, hard, 5x5mm, adherent and tender nodule in the left parotid region. There was no history of trauma or other symptoms.

Pre-operative work-up included: blood analysis which showed no relevant alteration; ultrasound which showed a 8x5mm, lobulated, hypoechoic nodule with liquid/cystic content; cytology which described a low grade epithelial / myoepithelial tumour and an MRI describing a bilobulated, 8x5mm, nodule with well-defined borders and a thin wall in the left superficial parotid gland with anterior extension to the masseter muscle.

Thus, we performed a superficial left parotidectomy using a retro-tragal mini-lifting approach. There were no complications during surgery and the facial nerve was preserved.

Follow-up included a pathology exam in which the tumour was described as a brownish-yellow well delimited nodule with a larger diameter of 0.4cm. Histology (Figure 1) showed an encapsulated neoplasia (A) with a cribriform/microcystic pattern. Neoplastic cells had irregular nuclei, eosinophilic cytoplasm and secretion product in the gland-like spaces (B). Immunohistochemically (Figure 2) the neoplastic cells were positive for CK7 (C), mammaglobin (D), GATA-3 (E) and S100 protein (F) and negative for DOG-1 (G) and P63 (H).

Adjunctive radiotherapy with a total dose of 60Gy was also performed and, to date, the patient remains asymptomatic with no signs of recurrence.

DISCUSSION

MASC is, generally, a solitary², firm/rubbery mass with a white to grey cut surface³. Fluid-filled cystic spaces may be seen³. Perineural invasion and extension to extra-glandular tissues occurs often but lymphovascular invasion and necrosis are uncommon^{2,3}. Histologically it is a well-defined multilobulated tumor divided into segments by fibrous septa⁴. Neoplastic cells have uniform and round nuclei³ with centrally located small nucleoli and eosinophilic vacuolated cytoplasm, and can be arranged in microcystic, cribriform, tubular, papillary, follicular or solid nests pattern^{3,4}. Microscopic foci of invasion can be present although atypia is generally mild and mitotic activity is scarce^{3,4}. Immunohistochemically, it is positive for a wide-spectrum of cytokeratins (AE1-AE3, CAM5.2, CK7, CK8, CK18, CK19), S100 protein, mammaglobin and, in most cases, GCDFP-15, SOX10, GATA-3 and vimentin^{3,4}. Basal cell / myoepithelial markers such as p63, calponin, CK14, SMA, and CK5/6 are virtually always negative. Most cases are negative for DOG-1³.

Genetically, a t(12;15)(p13;q25) translocation resulting in the ETV6-NTRK3 fusion gene is present⁴. ETV6 is a transcriptional regulator and NTRK3 is a membrane receptor kinase³. The fusion gene results in a ligand independent activation of the kinase thus promoting cell proliferation and survival^{2,3}. This fusion gene has not been described in other salivary gland tumours³.

Imagiologic descriptions are lacking in the literature. On MRI the tumour shows hyperintensity relative to muscle in T1 and hypointensity relative to the parotid gland in T2².

The treatment of choice in MASC is complete surgical resection (standard care for low grade salivary carcinomas)^{2,3}. Locoregional radiation is sometimes considered, mostly in cases with positive margins or perineural invasion³, although the impact on prognosis is not established². Systemic chemotherapy can be implemented if distant metastases are present³. Response to tyrosine kinase inhibitors has been described in other tumours with the ETV6 translocation but not in MASC³.

REFERENCES

1. Skálová A, Vanecek T, Sima R, Laco J, Weinreb I, Perez-Ordóñez B, et al. Mammary analogue secretory carcinoma of salivary glands, containing the ETV6-NTRK3

fusion gene: A hitherto undescribed salivary gland tumor entity. *Am J Surg Pathol.* 2010;34(5):599-608. DOI: 10.1097/PAS.0b013e3181d9efcc.

2. Sethi R, Kozin E, Remenschneider A, Meier J, VanderLaan P, Faquin W, et al. Mammary analogue secretory carcinoma: Update on a new diagnosis of salivary gland malignancy. *Laryngoscope.* 2014;124(1):188-95. DOI: 10.1002/lary.24254.
3. Skálová A, Gnepp DR, Lewis JS Jr, Hunt JL, Bishop JA, Hellquist H, et al. Newly Described Entities in Salivary Gland Pathology. *Am J Surg Pathol.* 2017;41(8):e33-e47. DOI: 10.1097/PAS.0000000000000883.
4. Damjanov I, Skenderi F, Vranic S. Mammary Analogue Secretory Carcinoma (MASC) of the salivary gland: A new tumor entity. *Bosn J Basic Med Sci.* 2016;16(3):237-8. DOI: 10.17305/bjbms.2016.1321.
5. Ngouajio AL, Drejet SM, Phillips DR, Summerlin DJ, Dahl JP. A systematic review including an additional pediatric case report: Pediatric cases of mammary analogue secretory carcinoma. *Int J Pediatr Otorhinolaryngol.* 2017;100:187-93. DOI: 10.1016/j.ijporl.2017.07.004.

Figure 1. Histology showed an encapsulated neoplasia (A) with a cribriform/microcystic pattern. Neoplastic cells had irregular nuclei, eosinophilic cytoplasm and secretion product in the gland-like spaces (B).

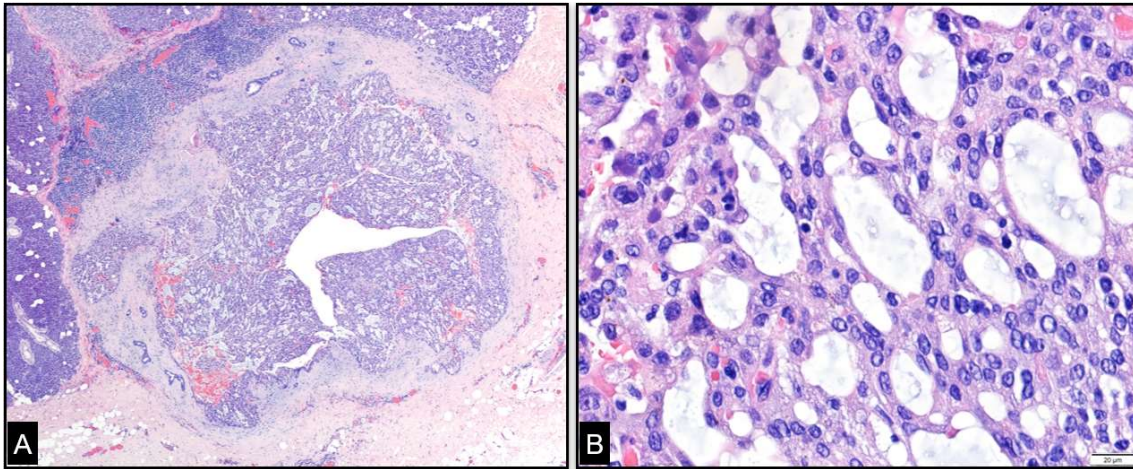


Figure 2. Immunohistochemically the neoplastic cells were positive for CK7 (C), mammaglobin (D), GATA-3 (E) and S100 protein (F) and negative for DOG-1 (G) and P63 (H).

